

the celiac axis after the operation.

The available evidence demonstrates that both laparoscopic and open ligament release associated with celiac ganglionectomy are effective in provide celiac artery revascularization and sustained symptom relief in the majority of patients with the syndrome^{2,3,5}. The laparoscopic approach is feasible, safe, and successful, if performed by experienced laparoscopic surgeons.

Although the laparoscopic treatment of celiac axis compression syndrome is a new technique, several authors have demonstrated its affectivity in providing symptom relief in patients^{1,2,8}. In addition, this access has several advantages, such as reduction of postoperative pain and blood loss, shorter hospital stay and faster recovery.

More recently, this syndrome has been effectively treated with robot-assisted surgery³. The advantages of this approach compared to the laparoscopic access have not yet been completely evaluated. The high cost of robot-assisted surgery is an important drawback in our country.

REFERENCES

- Berard X, Cau J, Déglise S, Trombert D, Saint-Lebes B, Midy D, Corpataux JM, Ricco JB. Laparoscopic surgery for coeliac artery compression syndrome: current management and technical aspects. *Eur J Vasc Endovasc Surg* 2012;43:38-42.
- di Libero L, Varricchio A, Tartaglia E, Iazzetta I, Tartaglia A, Bernardo A, Bernardo R, Triscino G, Conte DL. Laparoscopic treatment of celiac axis compression syndrome (CACS) and hiatal hernia: Case report with bleeding complications and review. *Int J Surg Case Rep*. 2013;4:882-5.
- Do MV, Smith TA, Bazan HA, Stembergh III WC, Abbas AE, Richardson WD. Laparoscopic versus robot-assisted surgery for median arcuate ligaments syndrome. *Surg Endosc* 2013;27:4060-6.
- Dunbar JD, Molnar W, Beman FF, Marable SA. Compression of the celiac trunk and abdominal angina. *Am J Roentgenol Radium Ther Nud Med* 1965;95:731-44.
- França LHG, Mottin C. Surgical treatment of Dunbar syndrome. *J Vasc Bras* 2013;12:57-61.
- Harjola PT. A rare obstruction of the coeliac artery: report of a case. *Ann Chir Gynaecol Fenn* 1963;52:547-50.
- Palmer OP, Tedesco M, Casey K, Lee JT, Poultides GA. Hybrid Treatment of Celiac Artery Compression (Median Arcuate Ligament) Syndrome. *Dig Dis Sci* 2012;57:1782-5.
- Roayaie S, Jossart G, Gitlitz D, Lamparello P, Hollier L, Gagner M. Laparoscopic release of celiac artery compression syndrome facilitated by laparoscopic ultrasound scanning to confirm restoration of flow. *J Vasc Surg* 2000;32:814-7.

ABCD DV/1152

ABCD Arq Bras Cir Dig Letter to the Editor
2015;28(4):296

DOI: /10.1590/S0102-6720201500030021

INTRA-ABDOMINAL SEMINOMA TESTIS IN ADULT: CASE REPORT

Seminoma em testículo intra-abdominal de adulto: relato de caso

Jorge Roberto Marcante **CARLOTTO**¹, Ramiro **COLLEONI-NETO**¹, David Carlos **SHIGUEOKA**², Ricardo **ARTIGIANI-NETO**³, Gaspar de Jesus **LOPES-FILHO**¹

From the ¹Disciplina de Gastroenterologia Cirúrgica do Departamento de Cirurgia; ²Departamento de Diagnóstico por Imagem; and ³Departamento de Patologia da Escola Paulista de Medicina, Universidade Federal de São Paulo (¹Surgical Gastroenterology Discipline, Department of Surgery; ²Department of Diagnostic Imaging; and ³Department of Pathology of Paulista School of Medicine, Federal University of São Paulo), São Paulo, SP, Brazil

Financial source: none
Conflicts of interest: none

Correspondence:

Ramiro Colleoni Neto
E-mail: rcolleoni@uol.com.br

Received for publication: 09/12/2014
Accepted for publication: 28/05/2015

INTRODUCTION

The cryptorchidism is the most common congenital malformation of the genitourinary tract⁴. The intra-abdominal testicle is subject to complications such as cancer, ischemia and infertility¹. The most common malignant transformation of undescended testicle is the seminoma^{2,3,5}. Here is presented a case of adult massive pelvic mass corresponding to seminoma developed in intra-abdominal testis.

CASE REPORT

MC'S, man, 32, with a history of progressive and painless increased abdominal size four weeks ago, no other complaints. He had also several congenital malformations including: pectus excavatum, congenital dislocation of the hip and clubfoot (operated in childhood). Physical examination revealed ascites, bilateral pleural effusion and a hardened mass located in flank and the right iliac fossa of about 20 cm. Was detected the absence of the right testicle in scrotum. No abnormal laboratory tests were present. Computed tomography and magnetic resonance imaging of the abdomen and pelvis showed ascites and heterogeneous pelvic mass (Figure 1). The cytological study of ascites and pleural effusion showed no neoplastic cells.

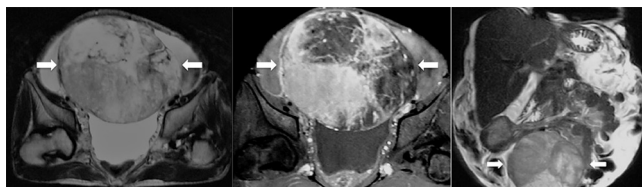


FIGURE 1 - MRI of the pelvis with heterogeneous mass with well vascularized with areas of degeneration/necrosis (arrows) and superior displacement of bowel loops

Laparotomy was performed which identified a large solid mass in the right iliac fossa partially adhered to the right inguinal canal, and dry easily. The surgical specimen measured 25x19x12 cm and weighed 2350 g (Figure 2). Histopathological examination revealed seminoma of undescended testis with extensive area of coagulation necrosis and angiolymphatic neoplastic embolization.

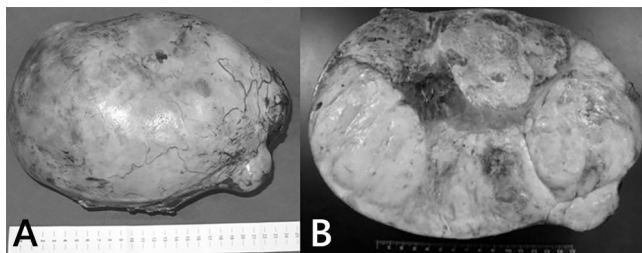


FIGURE 2 - Tumor mass with smooth outer surface, opaque, sometimes lobed, with brown bleeding areas in A. When cut, in B, whitish, firm and elastic tumor, permeated by areas of bleeding and yellowish and softened areas.

The patient was discharged on the sixth day after surgery. The left testicle was evaluated and was normal. The staging was completed and once considered the patient in stage III (ascites), was subjected to four cycles of chemotherapy with bleomycin, etoposide and cisplatin, keeping normalization of markers and improvement of ascites. He is currently with eight years of evolution, and in that period maintained regular outpatient follow-up showing no measurable disease to blood tests and imaging.

DISCUSSION

The cryptorchidism results from abnormalities in the formation and testicular descent during the embryonic period⁴. It is present in 6% of newborns at term and in 0.8% of infants under one year of age. Can be bilateral in up to 10% of cases, and sometimes is associated with other defects in genitourinary tract⁵.

The most feared complication of undescended testicle is cancer, ranging from 3.5-14.5% among patients with cryptorchidism⁵. The testis are intra-abdominal in 10% of cases and at risk 200 times greater in malignant transformation³. Malignant degeneration has the peak incidence in third and fourth decade of life^{2,3}. They are usually asymptomatic and are identified incidentally by imaging tests. When symptomatic, diagnosis is difficult and the symptoms may mimic acute appendicitis, urinary calculus and mass effects, compressive symptoms of the gastrointestinal and genitourinary tracts³. Imaging tests, US, CT and MRI show pelvic or retroperitoneal mass, well defined, homogeneous, without obvious evidence of necrosis or calcification^{2,3,5}. These findings have as main differential diagnoses lymphadenopathy and sarcoma, which are more common situations. The predominant histological type is pure seminoma (43%), followed by embryonic carcinoma (28%), teratocarcinoma (27%) and choriocarcinoma (2%)³. Surgical treatment is mandatory, with resection of intra-abdominal mass and chemotherapy may be an alternative, depending on the stage and histological type of malignant transformation².

REFERENCES

1. Küçük HF, Dalkılıç G, Kuroğlu E, Altuntaş M, Barişik NO, Gülmen M. Massive bleeding caused by rupture of intra-abdominal testicular seminoma: case report. *J Trauma*. 2002 May;52(5):1000-1.
2. Lim YJ, Jeong MJ, Bae BN, Kim SH, Kim JY. Seminoma in undescended testis. *Abdom Imaging*. 2008 Mar-Apr;33(2):241-3.
3. Miller FH, Whitney WS, Fitzgerald SW, Miller EI. Seminomas complicating undescended intraabdominal testes in patients with prior negative findings from surgical exploration. *AJR Am J Roentgenol*. 1999 Feb;172(2):425-8.
4. Wood HM, Elder JS. Cryptorchidism and testicular cancer: separating fact from fiction. *J Urol*. 2009 Feb;181(2):452-61.
5. Woodward PJ. Case 70: seminoma in an undescended testis. *Radiology*. 2004 May;231(2):388-92.

ABCDDV/1153

ABCD Arq Bras Cir Dig Letter to the Editor
2015;28(4):297

DOI: /10.1590/S0102-6720201500030022

LATE SURGICAL TREATMENT FOR SPONTANEOUS RUPTURE OF HEPATOCELLULAR ADENOMA: CASE REPORT

Tratamento cirúrgico tardio para ruptura espontânea de adenoma hepatocelular: relato de caso

Luis Eduardo Veras **PINTO**, João Paulo Ribeiro **SILVA**, Gustavo Coêlho **RÊGO**, José Huygens Parente **GARCIA**

From the Departamento de Cirurgia do Hospital Universitário Walter Cantídio (Hospital das Clínicas), Serviço de Cirurgia do Aparelho Digestivo, Universidade Federal do Ceará (Department of Surgery, University Hospital Walter Cantídio, Digestive Surgery Service, Federal University of Ceará), Fortaleza, CE, Brazil

Financial source: none
Conflicts of interest: none

Correspondence:

Luis Eduardo Veras Pinto
E-mail: luiseduardoveras@hotmail.com

Received for publication: 18/09/2014
Accepted for publication: 26/03/2015

INTRODUCTION

Hepatocellular adenoma (HA) is a rare benign neoplasm of the liver. It is strongly associated with oral contraceptive used by woman in childbearing age, by men receiving anabolic steroids and metabolic diseases. HA incidence has raised over the years from 5 per 1 million in 1964⁹ to 4 per 100.000³, for unknown reasons.

HA is important because of its risk of complications such as life threatening rupture of the tumor and malignant transformation. Surgical treatment in ruptured HA has a high mortality rate but it is still the standard procedure in those cases⁵. Emergency liver resection in ruptured HA has a mortality rate from 5-10%, but in elective resections the mortality rate is under 1%.

Different procedures have been suggested to decrease mortality rates and spare liver parenchyma, such as arterial embolization of ruptured adenomas, although it is not an available procedure in most centers.

CASE REPORT

A 44-year-old woman admitted in the emergency department of another hospital with complaints of sudden upper quadrant abdominal pain. She had been using oral contraceptives for 31 years. She presented with acute mild abdominal pain in epigastrium as well as right hypochondrium pain followed by light dyspnea and dizziness. She was treated with analgesics and ordered an abdominal ultrasound made only three days after the pain. The ultrasound showed a solid liver mass in the right hepatic lobe measuring 150x100x100 mm³. She was discharged without additional treatment.

After almost five months after the occurrence, she was referred to our surgical department for diagnostic investigation after another episode of abdominal pain just like the last time, followed by tachycardia and cold sweating. Physical examination revealed mild anemia and a diffuse abdominal pain, without peritonitis or palpable masses.

Lab exams showed 8.61g/dl haemoglobin, white blood count 8.980/mm³ and 214.00 platelets. Liver transaminases level were altered: ALT 306 IU/l, AST 154 IU/l, alkaline phosphatase 142 IU/l and gamma-glutamyl transferase 229 IU/l. Alfa-fetoprotein and clotting functions were normal.

Abdominal CT and MRI showed an enlarged liver, with a contrast enhanced liver mass involving segments VI and VII. The liver mass measured 118x70mm² associated with a perilesional voluminous hematoma measuring 8cm and haemoperitoneum. The radiologic findings suggested a ruptured hepatocellular adenoma (Figure 1)

Patient was admitted and sent to observation room to be prepared for surgical procedure after clinical improvement. She was transfused with two bags of packed red blood cells and intensive electrolytes control. Patient was sent to the operation room and had an open laparotomy with Chevron incision. During operative exploration was found a voluminous liver lesion involving segments VI and VII, large subcapsular hematoma over the right hepatic lobe and mild hemoperitoneum. The right lobe of the liver had strong adhesions to the right diaphragm. It was decided to make an anterior approach with inflow control due to the risk of bleeding, by ligation of the right portal vein and the right hepatic artery. The procedure continued with parenchyma right transection in the cantlie's line, showed