

## LAPAROSCOPIC TRANSTHORACIC LIVER RESECTION

*Hepatectomia laparoscópica transtorácica*

Jaime Arthur Pirola **KRÜGER**, Fabrício Ferreira **COELHO**, Marcos Vinícius **PERINI**, Paulo **HERMAN**

From the Serviço de Cirurgia do Fígado e Hipertensão Portal, Departamento de Gastroenterologia, Hospital das Clínicas, Faculdade de Medicina da Universidade de São Paulo (Liver Surgery Unit, Hospital das Clínicas, School of Medicine, University of São Paulo), São Paulo, SP, Brazil

**HEADINGS** - Hepatectomy. Laparoscopy. Minimally invasive surgical procedures. Tissue adhesions.

### Correspondence:

Jaime Arthur Pirola Krüger.  
E-mail: [jaimearthur@yahoo.com](mailto:jaimearthur@yahoo.com)

Financial source: none  
Conflicts of interest: none

Received for publication: 29/07/2014  
Accepted for publication: 30/09/2014

**DESCRITORES** - Hepatectomia. Laparoscopia. Procedimentos cirúrgicos de mínimo acesso. Aderências teciduais.

**ABSTRACT - Introduction:** Minimally invasive laparoscopic liver surgery is being performed with increased frequency. Lesions located on the anterior and lateral liver segments are easier to approach through laparoscopy. On the other hand, laparoscopic access to posterior and superior segments is less frequent and technically demanding. **Aim:** Technical description for laparoscopic transthoracic access employed on hepatic wedge resection. **Technique:** Laparoscopic transthoracic hepatic wedge resection on segment 8. **Conclusion:** Transthoracic approach allows access to the posterior and superior segments of the liver, and should be considered for oddly located tumors and in patients with numerous previous abdominal interventions.

**RESUMO - Introdução:** As ressecções hepáticas minimamente invasivas vêm sendo realizadas com frequência crescente. O fígado é facilmente abordável através de laparoscopia para o tratamento de lesões localizadas nos segmentos anteriores e laterais; porém, o acesso aos segmentos posteriores é infrequente e tecnicamente difícil. **Objetivo:** Descrever a técnica empregada no acesso laparoscópico transtorácico para realização de ressecção hepática. **Técnica:** Ressecção hepática em cunha no segmento 8 do fígado realizada através de laparoscopia com auxílio de portais transtorácicos. **Conclusão:** A abordagem transtorácica permite o acesso à parte posterior e aos segmentos superiores do fígado; deve ser considerada para tumores localizados excêntricamente, e em pacientes com numerosas intervenções abdominais anteriores.

## INTRODUCTION

The liver is located on the right upper quadrant, with most of its surface covered by the costal cage and the diaphragm. Such placement limits surgical access, demanding extended laparotomies and potent retractors to achieve adequate exposure<sup>1</sup>.

Laparoscopy provides easy access to anterior and lateral hepatic segments (2, 3, 4b, 5 and 6)<sup>2,3</sup>. Not the same can be said about segments 7, 8 and 4a. These posterior-superior segments are difficult to approach through standard laparoscopic view. This technical limitation for access and adequate view results in longer operative time, difficulty to obtain adequate margins, increased blood loss and higher conversion rates<sup>4</sup>.

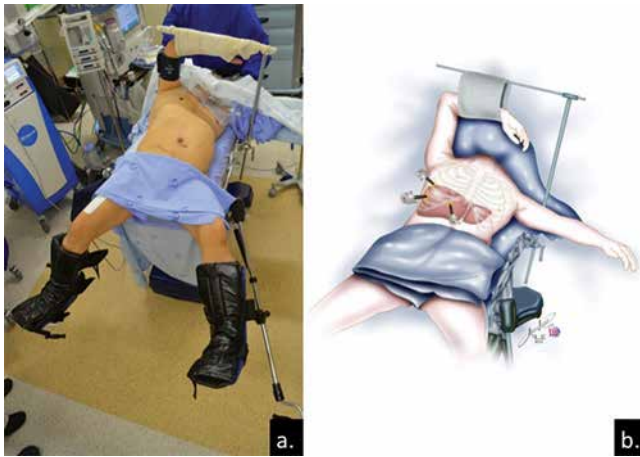Another limitation for laparoscopy is multiple previous open abdominal operations, which results in formation of adhesions that may hamper the minimally invasive approach<sup>5</sup>.

The aim of this article is to demonstrate de technical description for laparoscopic transthoracic access employed on hepatic wedge resection.

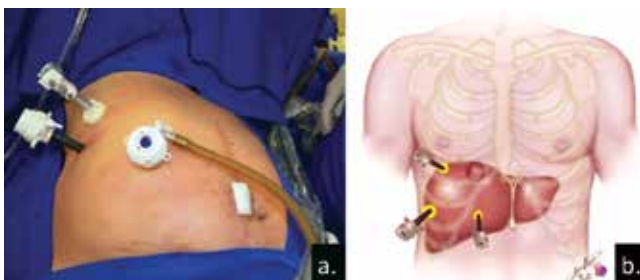## TECHNIQUE

Transthoracic laparoscopic approach is done with following technique. Patient is placed in French position, with a semi-left lateral decubitus (right arm placed on an arm board over patient's chest) (Figure 1a). The access to peritoneal cavity is made in open fashion, 2 cm under the right costal cage on the anterior axillary line (10 mm port). Other 2 ports are placed through the right hemi-thorax: one on the middle axillary line on the 11<sup>th</sup> intercostal space (12 mm – optical) and another port on the anterior axillary line at the 9<sup>th</sup> intercostal space (10 mm) (Figures 1b, 2a and 2b). The transthoracic ports go through the diaphragm into the peritoneal cavity.

## RESULT

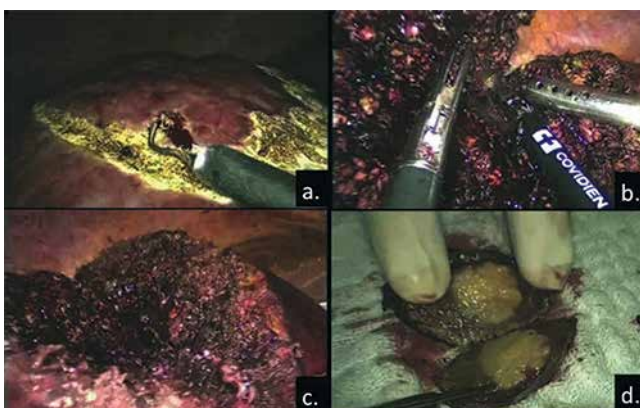


**FIGURE 1** - Patient position: a) semi-left lateral decubitus; b) position of the trocars showing the access to the hepatic dome



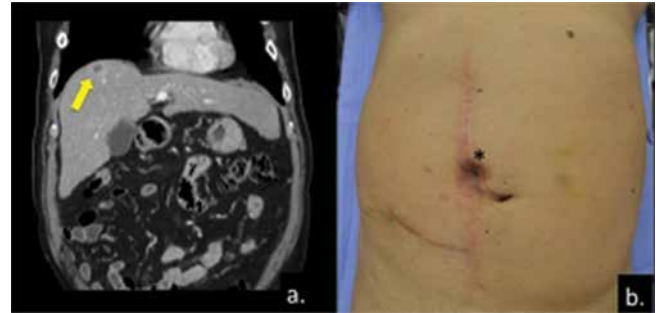
**FIGURE 2** - Port placement: a) one 10 mm trocar at 2 cm under the right costal cage on the anterior axillary line; one 12 mm on the middle axillary line on the 11th intercostal space; one 10 mm on the anterior axillary line at the 9th intercostal space; b) drawing showing the correspondent interior position of the trocars

Intraoperative ultrasound is necessary to confirmed the location of the nodule and margins are delineated with monopolar cautery (Figure 3a). A 10 mm 30° optic is used and pnemoperitoneum is set under 12 mmHg pressure. Parenchymal transection is carried out employing a bipolar sealing device (LigaSure 5mm BluntTip™, Covidien, Boulder, CO, USA) (Figures 3b and 3c). The raw surface was covered with an absorbable hemostatic tissue (Surgicell Fibrilar™, Ethicon, Sommerville, NJ). Surgical specimen (Figure 3d) is extracted on a plastic bag through the 10 mm port under the right costal cage. The diaphragm is closed with absorbable 2-0 poliglactine sutures and no drains were left in the abdominal or thoracic cavity.



**FIGURE 3** - Intraoperative findings: a) surgical margins delineated; b) parenchymal transection; c) raw surface - final aspect; d) surgical specimen

This operation was used in a 65-year-old man with a hepatic nodule incidentally found during preoperative work-up for correction of a large incisional hernia. Computed tomography showed a 2.0 cm lesion located on segment VIII (Figure 4a). The patient had undergone 11 abdominal interventions during the last 20 years due to a complicated appendicitis with multiple reoperations, including two attempts to correct the ventral hernia (Figure 4b).



**FIGURE 4** – a) Hepatocellular carcinoma located on segment 8 (arrow); b) abdominal incisions from previous interventions and fistulous orifice (\*)

Operative time was 75 minutes and estimated blood loss was 20 ml. No intensive care unit was needed and the patient had an uneventful outcome. Hospital discharge was on the second post-operative day. Pathology confirmed a moderately differentiated hepatocellular carcinoma. Computed tomography scan on the 4<sup>th</sup> month follow-up showed no signs of recurrence.

## DISCUSSION

Laparoscopic liver resection is constantly evolving. Initial experience with minimally invasive liver resection focused on the antero-lateral segments (2, 3, 4b, 5 e 6) and on minor resections (less than three segments), which were easier to accomplish. As a clear sign of improved technique, in 2008 left lateral sectionectomy was already considered the gold-standard approach for lesions on segments II and III<sup>2</sup>. On the other hand, posterior segments are difficult to approach. The visual field is limited on the traditional laparoscopic view, once it visualizes the liver from its visceral surface. This view results in a great amount of parenchyma interposed between what is seen and what the surgeon is operating on. Beside visual limitation, the posterior sector is attached to the retroperitoneum and the diaphragm (right triangular and coronary ligaments), demanding extensive dissection and mobilization in order to rotate the right hemiliver for exposure. Those limitations result in longer operative times, greater blood loss and higher conversion rates<sup>4</sup>.

The literature presents interesting case series in which those limitations were overcome with the use of hybrid techniques, hand assisted techniques and transthoracic access<sup>5,7,8,9</sup>. Those strategies have made almost all kinds of hepatic resections possible, with safety and good results.

The transthoracic approach is known since the era of open surgery, where some institutions used it for extended resections on the posterior liver or for simultaneous liver and pulmonary interventions<sup>10,11,12</sup>. It was adapted to the new minimally invasive reality. The transthoracic approach in selected cases is a wise decision if one considers the liver almost fully covered by the costal cage. Another advantage is the avoidance of a hostile abdominal cavity in cases with previous numerous interventions and complications<sup>5</sup>.

The present case had a neoplastic nodule, located in a difficult to treat position and previous multiple abdominal operations. The transthoracic approach allowed an oncologically adequate minimally invasive treatment with good postoperative result.

Dedicated practice leads to good results and is capital to have a team with experienced surgeons on liver and laparoscopic surgery. The liver surgery unit at the Hospital das Clínicas - University of São Paulo School of Medicine has made over 180 minimally invasive liver cases. Hereby, is presented the Brazilian first laparoscopic transthoracic liver resection and the pioneer experience in Brazil.

## CONCLUSION

Transthoracic approach allows access to the posterior and superior segments of the liver, and should be considered for oddly located tumors and in patients with numerous previous abdominal interventions.

## REFERENCES

1. Wakabayashi G. Laparoscopic liver resection: how far can we go? *J Hepatobiliary Pancreat Surg* 2009; 16: 403–404.
2. Buell JF, Cherqui D, Geller DA, et al. The international position on laparoscopic liver surgery: the Louisville Statement, 2008. *Ann Surg* 2009; 250: 825–830.
3. Ishizawa T, Gumbs AA, Kokudo N, Gayet B. Laparoscopic segmentectomy of the liver from segment I to VIII. *Ann Surg* 2012; 256: 959–964.
4. Cho JY, Han HS, Yoon YS, et al. Experiences of laparoscopic liver resection including lesions in the posterosuperior segments of the liver. *Surg Endosc*. 2008; 22: 2344–2349.
5. Aikawa M, Miyazawa M, Okamoto K, Toshimitsu Y, Okada K, Ueno Y, Yamaguchi S, Koyama I. Thoracoscopic hepatectomy for malignant liver tumor. *Surg Endosc* 2013 DOI 10.1007/s00464-013-3128-8.
6. Nitta H, Sasaki A, Otsuka Y, Tsuchiya M, Kaneko H, Wakabayashi G. Impact of hybrid techniques on laparoscopic major hepatectomies. *J Hepatobiliary Pancreat Sci* 2013; 20: 111–113.
7. Soyama A, Takatsuki M, Adachi T, Kitasato A, Torashima Y, Natsuda K, Tanaka T, Yamaguchi I, Tanaka S, Kinoshita A, Kuroki T, Eguchi S. A hybrid method of laparoscopic-assisted open liver resection through a short upper midline laparotomy can be applied for all types of hepatectomies. *Surg Endosc* 2013 DOI 10.1007/s00464-013-3159-1.
8. Cardinal JS, Reddy SK, Tsung A, Marsh JW, Geller DA. Laparoscopic major hepatectomy: pure laparoscopic approach versus hand-assisted technique. *J Hepatobiliary Pancreat Sci* 2013; 20: 114–119.
9. Gumbs AA, Gayet B. Video: The Lateral Laparoscopic approach to lesions in the posterior segments. *J Gastrointest Surg* 2008; 12: 1154.
10. Pocard M, Sauvanet A, Regimbeau JM, Duwat O, Farges O, Belghiti J. Limits and benefits of exclusive transthoracic hepatectomy approach for patients with hepatocellular carcinoma. *Hepatogastroenterology* 2002; 49(43): 32–35.
11. Erdogan A, Ayten A, Kabukcu H, Demircan A. One-stage transthoracic operation for the treatment of right lung and liver hydatid cysts. *World J Surg* 2005; 29: 1680–1686.
12. Delis S, Madariaga J, Bakoyiannis A, Avgerinos C, Touloumis Z, Vasileios, Dervenis C. Combined liver and lung metastasectomy through an exclusive transthoracic approach. *Journal of Surgical Oncology* 2007; 96: 178–182.