

SCARLESS HEPATECTOMY: NATURAL ORIFICE SPECIMEN EXTRACTION AFTER LEFT LATERAL SECTIONECTOMY

Hepatectomia sem cicatriz: extração do espécime por orifício natural depois de seccionectomia lateral esquerda

Univaldo E. SAGAE^{1,3}, Ivan R. B. ORSO^{1,3}, Helin Minoru MATSUMOTO^{1,3}, Paulo HERMAN²

From the ¹Gastroclínica de Cascavel – Serviço de Cirurgia Gastrointestinal, Cascavel, PR; ²Faculdade de Medicina da Universidade de São Paulo, São Paulo, SP; Hospital São Lucas, Faculdade de Medicina da Faculdade Assis Gurgacz FAG (¹Cascavel Gastroclin - Gastrointestinal Surgery Unit, Cascavel, PR; ²University of São Paulo Medical School, Gastroenterology Department, Liver Surgery Unit, São Paulo, SP; ³São Lucas Hospital – Assis Gurgacz Faculty FAG School of Medicine, Cascavel, PR), Brazil

HEADINGS - Hepatectomy. Laparoscopy. Natural orifices endoscopy surgery. Surgical procedures. Liver neoplasms.

ABSTRACT - Background: The use of laparoscopy in liver surgery is well established and considered as the gold standard for small resections. The laparoscopic resections have lower morbidity and better cosmetic results, but still require an incision to remove the surgical specimen. The possibility of remove the specimen through natural orifices and avoid an abdominal incision may further improve the benefits offered by minimally invasive procedures. **Aim:** To describe the technique of transvaginal extraction of the specimen after laparoscopic liver left lateral sectionectomy. **Method:** The laparoscopic liver resection is performed in a standard fashion. After completing the resection, the specimen is placed into a retrieval plastic bag. To perform de extraction, a vaginal colpotomy is performed, guided by a 12 mm trocar introduced through the vagina. Then the extraction bag is removed pulling the bag through the extended incision in the posterior wall of the vagina. After the extraction, the colpotomy incision is closed laparoscopically. **Results:** This technique was performed in a 74-year-old woman with a 3 cm lesion between liver segments 2 and 3. She had a fast and uneventful recovery. **Conclusion:** This technique appears to be feasible, safe and avoid the complications of an abdominal incision.

Correspondence:

Ivan R. B. Orso
 ivan@gastro.com.br

Financial source: none
 Conflicts of interest: none

Received for publication: 24/06/2014
 Accepted for publication: 16/09/2014

DESCRIPTORES - Hepatectomia. Laparoscopia. Orifícios naturais. Endoscopia cirúrgica. Procedimentos cirúrgicos. Neoplasias hepáticas.

RESUMO - Racional: O uso da laparoscopia na cirurgia de fígado está bem estabelecida e considerada o padrão-ouro para pequenas ressecções. As ressecções laparoscópicas têm menor morbidade e melhor resultado estético, mas ainda requerem uma incisão para remover a peça cirúrgica. A possibilidade de retirar a amostra através de orifícios naturais e evitar incisão abdominal pode melhorar ainda mais os benefícios oferecidos pelos procedimentos minimamente invasivos. **Objetivo:** Descrever a técnica de extração transvaginal do espécime após seccionectomia hepática laparoscópica esquerda lateral. **Método:** A hepatectomia laparoscópica é realizada de forma padrão. Depois de completar a ressecção, a amostra é colocada dentro de um saco plástico de recuperação. Para a realização de extração, uma colpotomia vaginal é realizada, guiado por trocarte de 12 mm introduzido através da vagina. Em seguida, o saco é removido, puxando-o através da incisão estendida na parede posterior da vagina. Após a extração, a incisão da colpotomia é fechada por laparoscopia. **Resultados:** Esta técnica foi realizada em uma mulher de 74 anos de idade, por lesão de 3 cm entre os segmentos 2 e 3 do fígado Ela teve recuperação rápida e sem complicações. **Conclusão:** Esta técnica parece ser viável, segura e evitar as complicações de uma incisão abdominal.

INTRODUCTION

The use of laparoscopy for resection of liver lesions is increasing. This is due to lower morbidity, less postoperative pain, better cosmetic results and rapid return to daily activities with oncological results similar to conventional surgery¹⁻⁵.

Current techniques still require an abdominal incision to remove the surgical specimen. Despite this incision being smaller than the conventional incision, it can still cause pain and present complications such as hernia, infection, and a bad cosmetic result⁶. The possibility of a totally laparoscopic resection with removal of the specimen by a transvaginal route without the need for an abdominal incision can further enhance the proven benefits of laparoscopic liver resections.

The advantages of transvaginal extraction of the specimen has been shown in several case series and retrospective studies in colorectal surgery⁶⁻¹⁵. There are also reports of transvaginal specimen extraction after gastrectomy, splenectomy, nephrectomy and removal of gynecological tumors^{13,15,17,18}. The use of this technique in liver surgery is likely to show similar benefits.

The objective of this report is to describe the technique of transvaginal removal of the specimen after a left lateral liver sectionectomy (segments 2 and 3).

TECHNIQUE

The patient is placed in the lithotomy position and pneumoperitoneum established with CO₂ pressure maintained at 12 mmHg. Four ports are placed as showed in Figure 1.

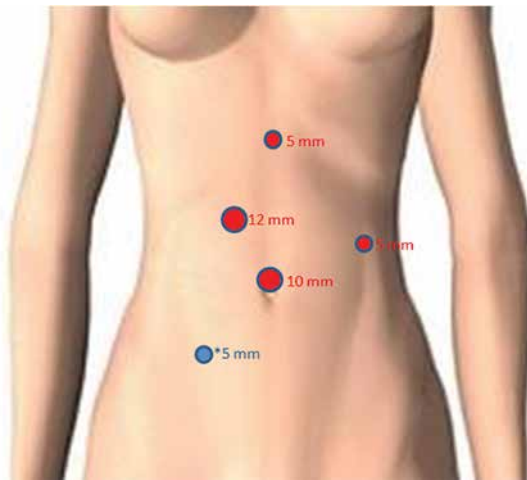


FIGURE 1 - Position of the trocars: In red, the ports used to perform the laparoscopic liver resection; in blue, the extra trocar placed to enlarge the colpotomy

Initially the cavity should be inspected and the location of the hepatic lesion identified. The left triangular ligament is released until near the trunk of the left hepatic vein. Then the lesser omentum is opened. The transection line located between segment 4 and segments 2 and 3 is marked near the falciform ligament with electrocautery. The parenchyma transection is performed using ultrasonic scalpel until the identification of the intraparenchymal pedicle. The pedicles of segments 2 and 3 should be sectioned with a laparoscopic stapler with vascular load. The transection of the parenchyma continue until the identification of the left hepatic vein which is also sectioned with vascular stapler, completing the left lateral segment resection. After the completing the resection, the specimen is placed into a retrieval plastic bag.

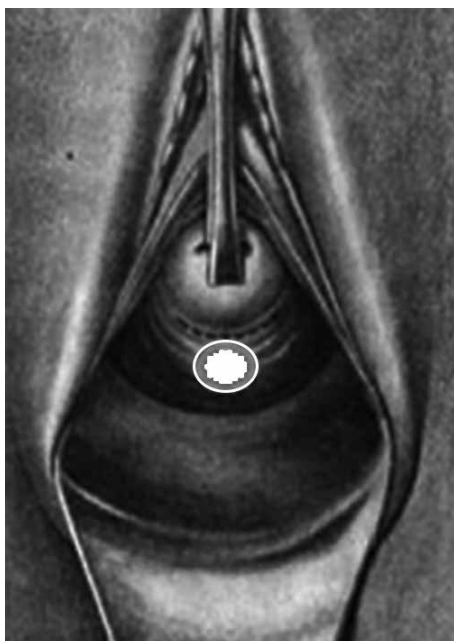


FIGURE 2 - Puncture site for the vaginal trocar

The vagina is cleansed using 10% povidone iodine solution. A 12 mm trocar is placed through the space of Douglas in the posterior vagina (Figure 2). The vaginal colpotomy is enlarged to 5 cm in length under laparoscopic view using ultrasonic scalpel, inserted through an extra abdominal 5 mm port in the right lower quadrant. The extraction bag with the specimen is gently removed pulling the bag through the extended incision in the posterior wall of the vagina using a grasper forceps (Figure 3). The colpotomy incision is closed laparoscopically with running suture and abdominal trocar wounds are closed in a standard fashion.

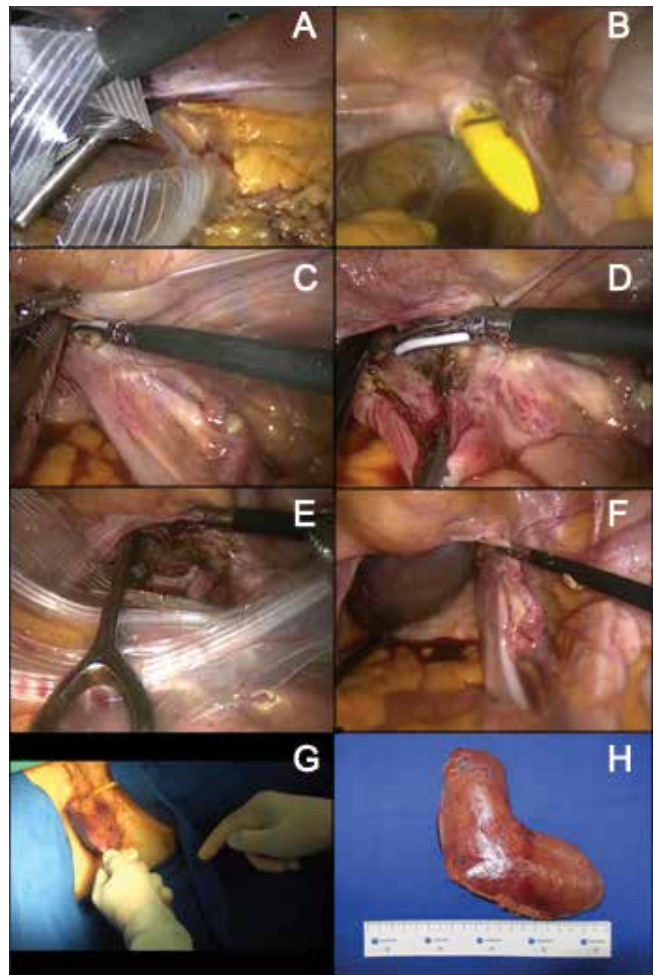


FIGURE 3 – A) The specimen placed into a retrieval bag; B) 12 mm trocar placed through the space of Douglas in the posterior vagina; C and D) the vaginal colpotomy enlarged to 5 cm in length using ultrasonic scalpel; E) grasper used to pull the extraction bag; F) extraction bag being pulled through the extended incision in the posterior wall of the vagina; G) external view; H) specimen after extraction

RESULTS

This technique has been applied to a 74-year-old white woman presenting a 3 cm lesion between liver segments 2 and 3. The tumor was diagnosed during a follow up CT scan after gastric GIST resection. No other lesions were identified and the surgical risk was considered to be low.

The patient had a fast recovery, walking and accepting diet in the same day of surgery. No vaginal complications occurred. She was discharged in the second postoperative day. The pathology report confirmed metastatic GIST.

DISCUSSION

Several reports of surgical transvaginal extraction of the specimen in colorectal surgery are available in the literature⁶⁻¹⁵. This technique is safe and easily applied, further reducing morbidity and improving the esthetic outcome in laparoscopic resection

Ongoing efforts aims to further reduce the surgical trauma associated with minimally invasive procedures. When considering morbidities associated with abdominal wall incisions and cosmetic results, this novel technique may have significant benefits compared with the traditional laparoscopic approach^{7,8,10-12,15}.

The predicted advantages of transvaginal extraction are reduced pain, a reduced rate of surgical site infection and a reduced rate of incisional hernia, achieved by the absence of a minilaparotomy¹⁵. Smaller incisions not only improve the cosmetic result, but also decrease postoperative pain, allow an early return to normal activities after the operation and reduce the morbidity rate which is directly associated with the incision length⁸.

Potential risks that are specifically attributed to the transvaginal route may include an increased risk of infertility and dyspareunia. The literature broadly suggests that sexual dysfunction is a rare event after transvaginal surgery^{8,10,15,16,18}. Complications directly related to the transvaginal access site, such as prolonged vaginal spotting or discharge, change in urinary or bowel control, perineal pain, are also uncommon. In an oncologic point of view, the available data show no reports of vaginal implants^{10,15}.

All these benefits can also be extended to selected cases of totally laparoscopic liver resection in female patients. When wedge resections, resections of isolated segments or bi-segmentectomies are performed, the specimen can be easily removed by this route.

CONCLUSION

Transvaginal specimen extraction following totally laparoscopic hepatectomy may be a good option for female patients who underwent small hepatectomies. Avoiding an abdominal incision, the postoperative pain and wound-related morbidity can be reduced. This technique appears to be safe, reproducible and present a low complication rate.

REFERENCES

1. Nguyen KT, Gamblin C, Geller D. World review of laparoscopic liver resection -2804 patients. *Ann Surg.* 2009; 250:831-841.
2. Buell JF, Cherqui D, Geller DA, O'Rourke N, Iannitti D, Dagher I, Koffron AJ, Thomas M, Gayet B, Han HS, Wakabayashi G, Belli G, Kaneko H, Ker CG, Scatton O, Laurent A, Abdalla EK, Chaudhury P, Dutson E, Gamblin C, D'Angelica M, Nagorney D, Testa G, Labow D, Manas D, Poon RT, Nelson H, Martin R, Clary B, Pinson WC, Martinie J, Vauthey JN, Goldstein R, Roayaie S, Barlet D, Espat J, Abecassis M, Rees M, Fong Y, McMasters KM, Broelsch C, Busuttil R, Belghiti J, Strasberg S, Chari RS. The international position on laparoscopic liver surgery. *Ann Surg.* 2009; 250:825-830.
3. Tsinberg M, Tellioglu G, Simpfendorfer CH, Walsh MR, Vogt D, Fung J, Berber E. Comparison of laparoscopic versus open liver tumor resection: a case-controlled study. *Surg Endosc.* 2009; 23:847-853.
4. Castaing D, Vibert E, Ricca L, Azoulay D, Adam R, Gayet B. Oncologic results of laparoscopic versus open hepatectomy for colorectal liver metastases in two specialized centers. *Ann Surg.* 2009; 250:849-855.
5. Herman P, Coelho FF, Lupinacci RM, Perini MV, Machado MAC, D'Albuquerque LAC, Ceconello I. Ressecções hepáticas por videolaparoscopia. *Arq Bras Cir Dig.* 2009; 22(4):226-232.
6. Park JS, Choi GS, Kim HJ, Park SY, Jun SH. Natural orifice specimen extraction versus conventional laparoscopically assisted right hemicolectomy. *Br J Surg.* 2011 May; 98(5):710-5.
7. Hottenrott, C. Right colectomy: is it a safe and feasible totally laparoscopic approach with transvaginal specimen extraction. *Surg Endosc.* 2011 May; 25(5):1699-700.
8. Park JS, Choi GS, Lim KH, Jang YS, Kim HJ, Park SY, Jun SH. Clinical outcome of laparoscopic right hemicolectomy with transvaginal resection, anastomosis, and retrieval of specimen. *Dis Colon Rectum.* 2010 Nov; 53(11):1473-9.
9. García Flórez LJ, Argüelles J, Quijada B, Alvarez V, Galarraga MA, Graña JL. Transvaginal specimen extraction in a laparoscopic anterior resection of a sigmoid colon neoplasia with en bloc right salpingo-oophorectomy. *Tech Coloproctol.* 2010 Jun; 14(2):161-3. Epub 2010 Feb 5.
10. McKenzie S, Baek JH, Wakabayashi M, Garcia-Aguilar J, Pigazzi A. Totally laparoscopic right colectomy with transvaginal specimen extraction: the authors' initial institutional experience. *Surg Endosc.* 2010 Aug; 24(8):2048-52. Epub 2010 Jan 28.
11. Franklin ME Jr, Kelley H, Kelley M, Brestan L, Portillo G, Torres J. Transvaginal extraction of the specimen after total laparoscopic right hemicolectomy with intracorporeal anastomosis. *Surg Laparosc Endosc Percutan Tech.* 2008 Jun; 18(3):294-8.
12. Palanivelu C, Rangarajan M, Jategaonkar PA, Anand NV. An innovative technique for colorectal specimen retrieval: a new era of "natural orifice specimen extraction" (N.O.S.E). *Dis Colon Rectum.* 2008 Jul; 51(7):1120-4.
13. Boni L, Tenconi S, Beretta P, Cromi A, Dionigi G, Rovera F, Dionigi R, Ghezzi F. Laparoscopic colorectal resections with transvaginal specimen extraction for severe endometriosis. *Surg Oncol.* 2007 Dec; 16 Suppl 1:S157-60.
14. Yoong W, Pillai R. Posterior colpotomy: a retrieval route for solid ovarian malignancies. *BJOG: An International Journal of Obstetrics and Gynaecology.* 2009; 465-466.
15. Diana M, Perretta S, Wall J, Costantino FA, Leroy J, Demartines N, Marescaux J. Transvaginal specimen extraction in colorectal surgery: current state of the art. *Colorectal Dis.* 2011 Jun; 13(6):e104-11.
16. Jeong SH, Lee YJ, Choi WJ, Paik WY, Jeong CY, Park ST, Choi SK, Hong SC, Jung EJ, Joo YT, Ha WS. Trans-vaginal specimen extraction following totally laparoscopic subtotal gastrectomy in early gastric cancer. *Gastric Cancer.* 2011 Mar; 14(1):91-6.
17. Box GN, Bessler M, Clayman RV. Transvaginal access: current experience and potential implications for urologic applications. *J Endourol.* 2009 May; 23(5):753-7.
18. Abrao MS, Sagae UE, Gonzales M, Podgaec S, Dias JA Jr. Treatment of rectosigmoid endometriosis by laparoscopically assisted vaginal rectosigmoidectomy. *Int J Gynaecol Obstet.* 2005; 91(1): 27-31.