



INTRA-ABDOMINAL PRESSURE MONITORING DURING LÁZARO DA SILVA'S PROCEDURE FOR VENTRAL HERNIA REPAIR: A CROSS-SECTIONAL STUDY

MONITORAMENTO DA PRESSÃO INTRA-ABDOMINAL DURANTE PROCEDIMENTO DE LÁZARO DA SILVA PARA CORREÇÃO DE HÉRNIA VENTRAL: ESTUDO TRANSVERSAL

Pedro Ducatti de OLIVEIRA E SILVA^{1,2}, Renato Miranda de MELO^{2,3},
Cássio Eduardo da Silva GONTIJO⁴, Ênio Chaves de OLIVEIRA^{1,3}

ABSTRACT – BACKGROUND: Maintaining normal intra-abdominal pressure (IAP) levels must be one major outcome of any ventral hernia repair, avoiding hypertension or abdominal compartment syndrome. **AIMS:** To evaluate IAP during ventral hernia repair using Lázaro da Silva's procedure. **METHODS:** IAP measurements using intravesical pressure were performed during four crucial intraoperative moments. Twenty-eight patients submitted to incisional herniorrhaphy were analyzed. **RESULTS:** The IAP increased by 0.5 mmHg during the procedure, regardless of the type of prior laparotomy, sex, age, obesity, or hernia width. **CONCLUSIONS:** Despite the IAP increase observed, Lázaro da Silva's procedure did not result in intra-abdominal hypertension or abdominal compartment syndrome.

HEADINGS: Ventral Hernia. Intra-Abdominal Hypertension. Herniorrhaphy.

RESUMO – RACIONAL: A manutenção dos níveis normais de pressão intra-abdominal (PIA) deve ser um dos principais resultados de qualquer correção de hérnia ventral, evitando hipertensão ou síndrome do compartimento abdominal. **OBJETIVOS:** Avaliar a PIA durante a correção de hérnia ventral pela técnica de Lázaro da Silva. **MÉTODOS:** As medidas da PIA por meio de pressão intravesical foram realizadas durante quatro momentos cruciais do intraoperatório. Foram analisados 28 pacientes submetidos à herniorrafia incisional. **RESULTADOS:** A PIA aumentou 0,5 mmHg durante o procedimento, independentemente do tipo de laparotomia prévia, sexo, idade, obesidade ou extensão da hérnia. **CONCLUSÕES:** Apesar do aumento da PIA observado, o procedimento de Lázaro da Silva não resultou em hipertensão intra-abdominal ou síndrome do compartimento abdominal.

DESCRIPTORIOS: Hérnia Ventral. Hérnia Incisional. Hipertensão Intra-Abdominal. Herniorrafia.

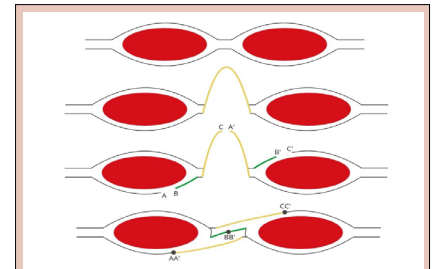


Figure 1 - Schematic representation of a transversal section of the Lázaro da Silva's procedure (i.e., longitudinal bilateral peritoneum-aponeurotic transposition). A: posterior-lateral flap; B: posterior-medial flap; C: right sac flap; A': left sac flap; B': anterior-medial flap; C': anterior-lateral flap; AA': first suture plane; BB': second plane; CC': third plane.

Central Message

Ventral hernia is considered a frequent complication after laparotomies, occurring in 10 to 23% of cases, or even at higher frequencies, according to the analyzed sample. Due to its physiopathology, midline ventral hernias promote shortening of the abdominal lateral musculature and lowering of the diaphragmatic dome, leading to a volumetric reduction of the abdominal cavity. In consequence, returning the herniated content to a smaller abdominal cavity can develop intra-abdominal hypertension, leading to abdominal compartment syndrome and catastrophic consequences for the patient.

Perspectives

Lázaro da Silva's procedure is a safe ventral hernia repair (VHR) technique and does not raise intra-abdominal pressure (IAP). Variation in IAP can occur within its physiological values and without causing clinical issues. Also, subgroup analysis of age, sex, prior laparotomy, diabetes mellitus, smoking, hernia width, and obesity did not interfere in IAP in this study.

[instagram.com/revistaabcd/](https://www.instagram.com/revistaabcd/) twitter.com/revista_abcd [facebook.com/Revista-ABCD-109005301640367](https://www.facebook.com/Revista-ABCD-109005301640367) [linkedin.com/company/revista-abcd](https://www.linkedin.com/company/revista-abcd)

From ¹Universidade Federal de Goiás, Faculty of Medicine, Postgraduate Program in Health Sciences – Goiânia (GO), Brazil; ²Hospital Geral de Goiânia Dr. Alberto Rassi – Goiânia (GO), Brazil; ³Universidade Federal de Goiás, Faculty of Medicine, Department of Surgery – Goiânia (GO), Brazil; ⁴Hospital Universitário de Brasília – Brasília (DF), Brazil.

How to cite this article: Oliveira e Silva PD, Melo RM, Gontijo CES, Oliveira EC. Intra-abdominal pressure monitoring during Lázaro da Silva's procedure for ventral hernia repair: a cross-sectional study. ABCD Arq Bras Cir Dig. 2024;37:e1813. <https://doi.org/10.1590/0102-6720202400020e1813>.

Correspondence: Pedro Ducatti de Oliveira e Silva.
E-mail: pedroducatti@gmail.com
Financial source: None
Conflict of interests: None
Received: 10/17/2023
Accepted: 05/16/2024

Editorial Support: National Council for Scientific and Technological Development (CNPq).

INTRODUCTION

Ventral hernia (VH) is considered a frequent complication after laparotomies, occurring in 10 to 23% of cases, or even at higher frequencies, according to the analyzed sample¹. It is a miscellaneous disease, with a broad severity spectrum, and yet a consensus defining a so-called “complex hernia” does not exist. Depending on the defect position on the abdominal wall, there are many surgical procedures to treat VH; the midline defects (both upper and lower) are the most frequent, also with higher surgical technique alternatives^{11,13}.

Ventral hernia repair (VHR) involves some challenges, such as reconstructing the abdominal wall while returning the herniated content to the abdominal cavity without significantly raising intra-abdominal pressure (IAP). Due to its physiopathology, midline VHs promote shortening of the abdominal lateral musculature and lowering of the diaphragmatic dome, leading to a volumetric reduction of the abdominal cavity. In consequence, returning the herniated content to a smaller abdominal cavity can develop intra-abdominal hypertension (IAH), leading to abdominal compartment syndrome (ACS) and catastrophic consequences for the patient^{2,13}. Therefore, achieving intra- and postoperative normal IAP levels should be an immediate outcome of VHR.

The VHR procedure developed by Alcino Lázaro da Silva (ALS), a former Brazilian surgeon, to treat large midline defects, has achieved good outcomes over the last 50 years^{6,7}. This is considered a tissue repair, thus sparing the use of synthetic meshes — majorly polypropylene. The advantage of this type of VHR can be observed in the long term, as synthetic meshes present with long-term complication rates of 5% and similar recurrence rates^{4,5}. Regarding this, Lázaro da Silva’s procedure shows long-term recurrence rates of 7.7%, similar to VHR employing synthetic meshes⁷.

Clinically, it is relevant to anticipate ACS and to guarantee that this complication does not occur during VHR of large defects, despite other preoperative efforts, such as preoperative pneumoperitoneum or botulinum toxin type A. Monitoring intra-abdominal pressure is a measure that can early diagnose IAH in order to avoid ACS.

Therefore, the purpose of this study was to evaluate IAP raising during Lázaro da Silva’s procedure for VHR, using intravesical pressure (IVP) monitoring.

METHODS

This is a cross-sectional and prospective study in which IAP was measured during VHR. Lázaro da Silva’s procedure, which is a bilateral longitudinal peritoneum-aponeurotic transposition described in 1971 (Figure 1), was chosen for the VHR. Figures 2, 3, and 4 show intraoperative photos of the Lázaro da Silva’s procedure.

Intra-operatively, IAP was measured through IVP (in mmHg) according to Kron’s method, using a 16-Fr Foley catheter and an electronic pressure transducer⁹. The IVP measurement occurred at four distinct surgical moments: immediately before surgical incision (moment 0; or t0) and after each one of the three suture planes of the VHR technique (moments 1, 2 and 3; or t1, t2, and t3). All patients had general anesthesia and epidural block.

This study included patients between 18 and 80 years old, presenting midline incisional hernias, without loss of domain, classified according to the European Hernia Society (EHS) ventral hernia classification¹⁰: M (midline) – M1 (subxiphoidal), M2 (epigastric), M3 (umbilical), M4 (infraumbilical), and M5

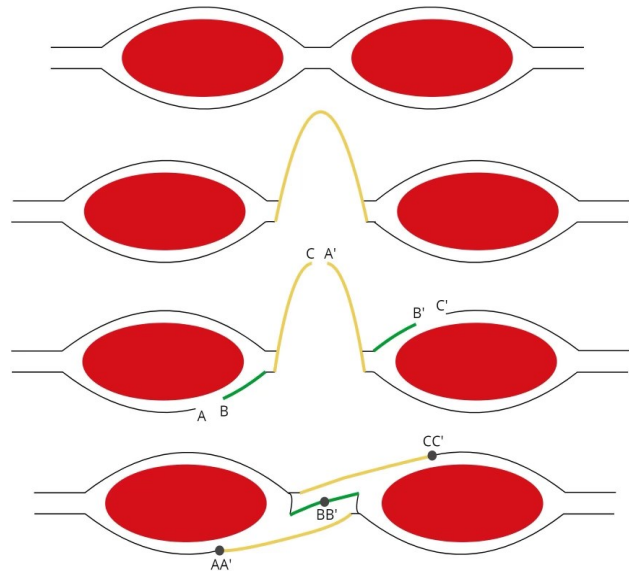


Figure 1 - Schematic representation of a transversal section of the Lázaro da Silva’s procedure (i.e., longitudinal bilateral peritoneum-aponeurotic transposition). A: posterior-lateral flap; B: posterior-medial flap; C: right sac flap; A’: left sac flap; B’: anterior-medial flap; C’: anterior-lateral flap; AA’: first suture plane; BB’: second plane; CC’: third plane.

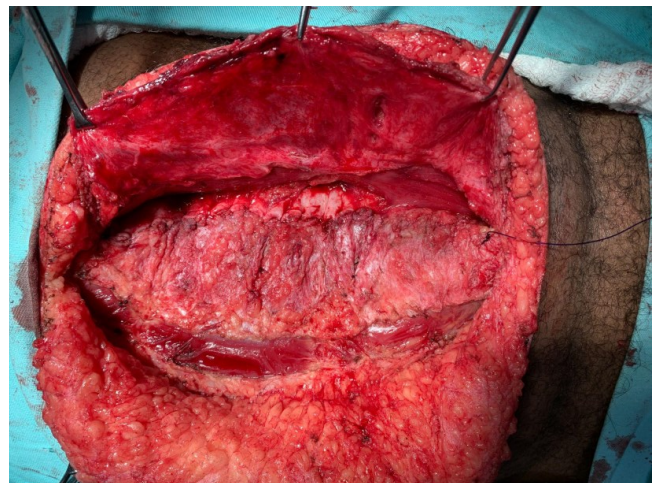

Figure 2 - Confection of the end of the first suture plane.

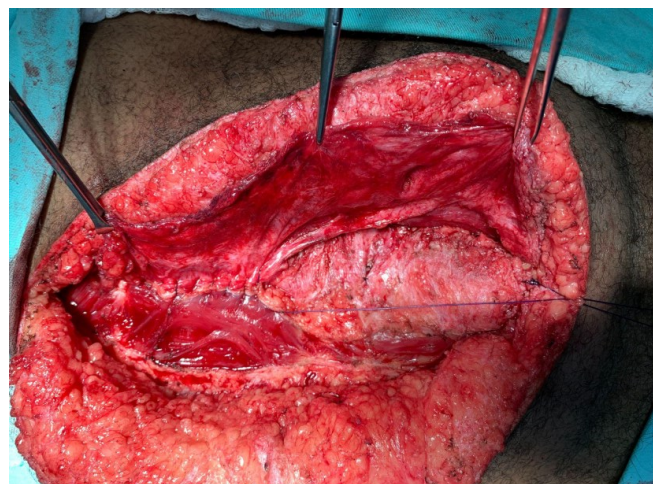


Figure 3 - Confection of the second suture plane.

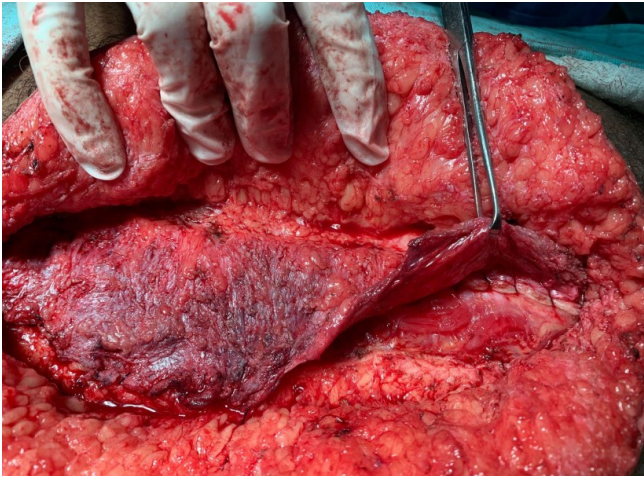


Figure 4 - Confection of the third suture plane.

(suprapubic); W (width) – W1 (less than 4 cm), W2 (between 4 and 10 cm), and W3 (more than 10 cm). Patients were excluded when the original Lázaro da Silva’s procedure was deemed not feasible.

The following parameters were evaluated: sex, age, prior laparotomy, enterotomy, obesity (body mass index [BMI] - kg/m²), diabetes mellitus, and smoking.

For IVP-related data, we employed central trend, symmetry, and value dispersion through analysis of variance (ANOVA), followed by *post-hoc* analysis using Bonferroni’s correction method. Statistical Package for Social Science (SPSS), version 26 (IBM Corporation, Armonk, USA) was employed for data analysis. The study was approved by the Ethics Committee of the institution (number 45878621.5.0000.0035).

RESULTS

Initially, 30 patients were included. Two of them were excluded from the analysis because the original Lázaro da Silva’s technique was not feasible. Demographic data of the remaining 28 patients are reported in Table 1. The sample was mostly female (64.3%), with conventional gastroplasty as prior laparotomy in 53.6%, and hernia diameter defect between 4 and 10 cm (EHS-W2) in 67.9%; 50.0% of the patients were over 60 years old, and 50.0% were obese (BMI > 30 kg/m²).

Mean values of IVP measured intra-operatively were: t0=5.53 (standard deviation [SD]±2.83) mmHg; t1=5.61 (±3.03) mmHg; t2=6.22 (±3.28) mmHg; and t3=6.19 (±2.27) mmHg. Median values were 5.50 mmHg, 6.00 mmHg, 6.00 mmHg, and 6.50 mmHg, respectively. There was a significant difference between the samples (p-value [p]<0.010). To identify the moment this difference occurred, a *post-hoc* analysis comparing each of the moments was performed (Figure 5). As a result, there was a significant difference only between moments t0 and t2 (p=0.019, p<0.050), with a 0.50 mmHg IAP raising. However, IAP values did not exceed normal pressure (i.e., lower than 12 mmHg).

In subgroups *post-hoc* analysis, interaction between IVP values of the following subgroups was tested: prior laparotomy (gastroplasty vs. other procedures; p=0.984); sex (male vs. female; p=0.981); age (<60 years vs. ≥60 years; p=0.971); obesity (BMI < 30 kg/m² vs. BMI ≥ 30 kg/m²; p=0.967); and defect width (EHS-W2 vs. EHS-W3; p=0.981). In summary, there was no significant difference in all studied groups.

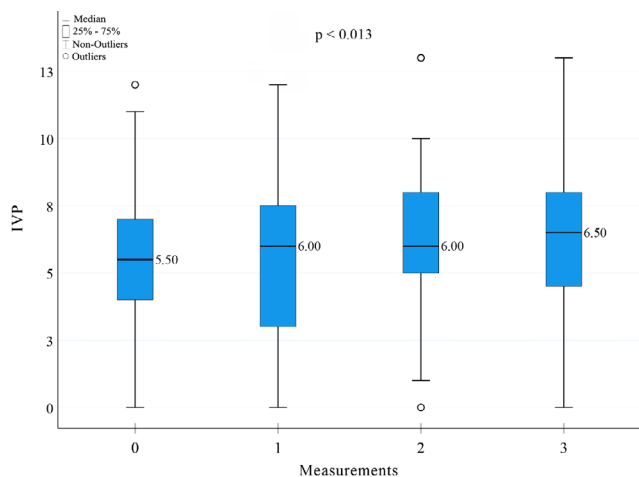
Table 1 - Demographic and anthropometric characteristics of the patients.

n=28	
	Mean±SD
Age (years)	56.32 ± 13.55
BMI (kg/m ²)	28.84 ± 5.32
Defect length (cm)	18.89 ± 5.20
Defect width (cm)	9.25 ± 3.43
n (%)	
Age group	
<60 years	14 (50.0)
≥60 years	14 (50.0)
Sex	
Female	18 (64.3)
Male	10 (35.7)
Prior laparotomy	
Gastroplasty	15 (53.6)
Others	13 (46.4)
Obesity	
No	14 (50.0)
Yes	14 (50.0)
Diabetes mellitus	
No	23 (82.1)
Yes	5 (17.9)
Smoking	
No	25 (89.3)
Yes	3 (10.7)
Enterotomy	
No	23 (82.1)
Yes	5 (17.9)
EHS-M	
M1–M2	4 (14.3)
M1–M3	15 (53.6)
M1–M4	3 (10.7)
M1–M5	2 (7.1)
M2–M3	1 (3.6)
M2–M4	1 (3.6)
M2–M5	1 (3.6)
M3–M5	1 (3.6)
EHS-W	
W2	19 (67.9)
W3	9 (32.1)

n: absolute frequency; %: relative frequency; SD: standard deviation; BMI: body mass index; M: midline; W: width; EHS-M: European Hernia Society midline; EHS-W: European Hernia Society width.

DISCUSSION

The results showed that Lázaro da Silva’s procedure can reconstruct the abdominal wall without raising the IAP. Variation in the physiologic values of IAP could have occurred and definitely happened. However, this elevation was anticipated, as the second suture plane (t2) involved suturing the aponeurotic defect and reconstructing the linea alba, while the other planes



IVP: intravesical pressure.

Figure 5 - Boxplot graphic with intravesical pressure results on the moments: before skin incision, and after each one of the suture planes of Lázaro da Silva's procedure, moments 0, 1, 2 and 3 respectively.

(t1 and t3) acted as lateral anchoring, which interfered less with the IAP values. Post-gastroplasty patients represented half of the study sample, which was initially a concern. However, subgroup analysis of prior laparotomy showed no significant difference ($p=0.984$, $p>0.050$).

Furthermore, VHR of an EHS-W2 without-loss-of-domain hernia (i.e., width between 4 and 10 cm) could rarely promote IAH or ACS, so this subgroup analysis was also relevant. Similarly to the other groups, there were no significant differences between EHS-W2 and EHS-W3 hernias. Plausible mechanisms for this phenomenon could be Lázaro da Silva's procedure itself: the relaxing incisions and the employment of the hernial sac could enlarge the abdominal cavity and raise its compliance.

Our data corroborate another experiment, using the same surgical procedure. In that experiment, ALS himself measured the IAP in 31 patients with a Teflon transabdominal catheter and registered similar values pre- and post-operatively⁸. Unlike in our study, IAP measures were not gathered intraoperatively nor were the anesthesia characteristics described (i.e., type of anesthesia, ventilation control, and neuromuscular blockade). Despite that, employing a controlled method and observing still intraoperatively, our study re-evaluated and confirmed the results obtained from that pioneer experiment.

In concern with ACS, Kirkpatrick et al. described its occurrence in VHR, developing the concept of quaternary abdominal compartment syndrome³. In illustration, working with the worst cases, another study evaluating 115 hernia patients with loss of domain showed 92% of IAH and 16% of ACS after VHR¹², using techniques other than Lázaro da Silva's procedure. In our sample, which had no loss of domain, we did not observe any clue of IAH. However, strict intraoperative checking of IAP is a fundamental measure in treating more complex hernias, as Quintela et al. observed higher rates of HIA and SCA¹².

Limitations of this study can be summarized in sample characterization, despite *post-hoc* analysis not demonstrating any impact on results. Evaluating and measuring IAP during Lázaro da Silva's procedure in the worst scenarios, like larger defects or with loss of domain, will be central to confirm the results obtained in this study. At least, in future research, we suggest a larger sample in order to encompass different clinical scenarios, though we recognize the difficulty in routinely measuring IAP.

CONCLUSIONS

Lázaro da Silva's procedure is a safe VHR technique and does not raise IAP. Variations in IAP can occur within its physiological values and without causing clinical issues. Also, subgroup analysis of age, sex, prior laparotomy, diabetes mellitus, smoking, hernia width, and obesity did not interfere with IAP in this study.

ACKNOWLEDGMENTS

We would like to acknowledge all preceptors of the Abdominal Wall Complex Hernia Fellowship Programme at Federal University of Goiás: Dr. Félix Sanches Penhavel, Dr. Fernando Correa Amorim, Dr. Edson Tadeu de Mendonça, and Dr. Renato Miranda de Melo.

REFERENCES

- Deerenberg EB, Harlaar JJ, Steyerberg EW, Lont HE, van Doorn HC, Heisterkamp J, et al. Small bites versus large bites for closure of abdominal midline incisions (STITCH): a double-blind, multicentre, randomised controlled trial. *Lancet*. 2015;386(10000):1254-60. [https://doi.org/10.1016/S0140-6736\(15\)60459-7](https://doi.org/10.1016/S0140-6736(15)60459-7)
- Kirkpatrick AW, Roberts DJ, De Waele J, Jaeschke R, Malbrain MLNG, De Keulenaer B, et al. Intra-abdominal hypertension and the abdominal compartment syndrome: Updated consensus definitions and clinical practice guidelines from the World Society of the Abdominal Compartment Syndrome. *Intensive Care Med*. 2013;39(7):1190-206. <https://doi.org/10.1007/s00134-013-2906-z>
- Kirkpatrick AW, Nickerson D, Roberts DJ, Rosen MJ, McBeth PB, Petro CC, et al. Intra-abdominal hypertension and abdominal compartment syndrome after abdominal wall reconstruction: quaternary syndromes? *Scand J Surg*. 2017;106(2):97-106. <https://doi.org/10.1177/1457496916660036>
- Klinge U, Krones CJ. Can we be sure that the meshes do improve the recurrence rates? *Hernia*. 2005;9(1):1-2. <https://doi.org/10.1007/s10029-004-0294-6>
- Kokotovic D, Bisgaard T, Helgstrand F. Long-term recurrence and complications associated with elective incisional hernia repair. *JAMA*. 2016;316(15):1575-82. <https://doi.org/10.1001/jama.2016.15217>
- Lázaro da Silva A. Plastic repair of the hernial sac in the correction of incisional hernias. *Hospital (Rio J)*. 1971;79(1):133-4. PMID: 4946964.
- Lázaro-da-Silva A, Vieira RG, Anjos GC. Recidivation of bilateral longitudinal peritoneum-aponeurotic transposition on incisional hernioplasty. *Arq Gastroenterol*. 2004;41(2):134-6. <https://doi.org/10.1590/s0004-28032004000200013>
- Lázaro-da-Silva A, Ferreira AP, Ribeiro V. Estudo eletromanométrico de pacientes com hérnia incisional. *Rev Col Bras Cir*. 1990;17(1/2):2-4.
- Malbrain MLNG. Different techniques to measure intra-abdominal pressure (IAP): time for a critical re-appraisal. *Intensive Care Med*. 2004;30(3):357-71. <https://doi.org/10.1007/s00134-003-2107-2>
- Muysoms FE, Miserez M, Berrevoet F, Campanelli G, Champault GG, Chelala E, et al. Classification of primary and incisional abdominal wall hernias. *Hernia*. 2009;13(4):407-14. <https://doi.org/10.1007/s10029-009-0518-x>
- Pereira-Rodrigues AK, Maceio-Da-Graça JVS, Ferreira EMLO, Alves-Almeida CC. Onlay versus Rives-Stoppa techniques in the treatment of incisional hernias. *Arq Bras Cir Dig*. 2023;36:e1766. <https://doi.org/10.1590/0102-672020230048e1766>

12. Quintela C, Freire L, Marrana F, Barbosa E, Guerreiro E, Ferreira FC. Quaternary abdominal compartment syndrome in complex ventral hernias. *International Journal of Abdominal Wall and Hernia Surgery*. 2021;4(2):39-44. https://doi.org/10.4103/ijawhs.ijawhs_43_20
13. Tustumi F, Darce GFB, Lobo Filho MM, Abdalla RZ, Costa TN. Stapled fascial closure vs. Continuous hand-sewn suture: experimental study of the abdominal wall on porcine model and human cadaver. *Arq Bras Cir Dig*. 2024;37:e1800. <https://doi.org/10.1590/0102-672020240007e1800>