ABCD Arq Bras Cir Dig
2026;39:e1986
https://doi.org/10.1590/0102-672020260000057e1986

REVIEW ARTICLE - POSITION PAPER

Liver resection, transplantation, and local therapies for hepatocellular carcinoma: a Brazilian multidisciplinary consensus

VISUAL ABSTRACT

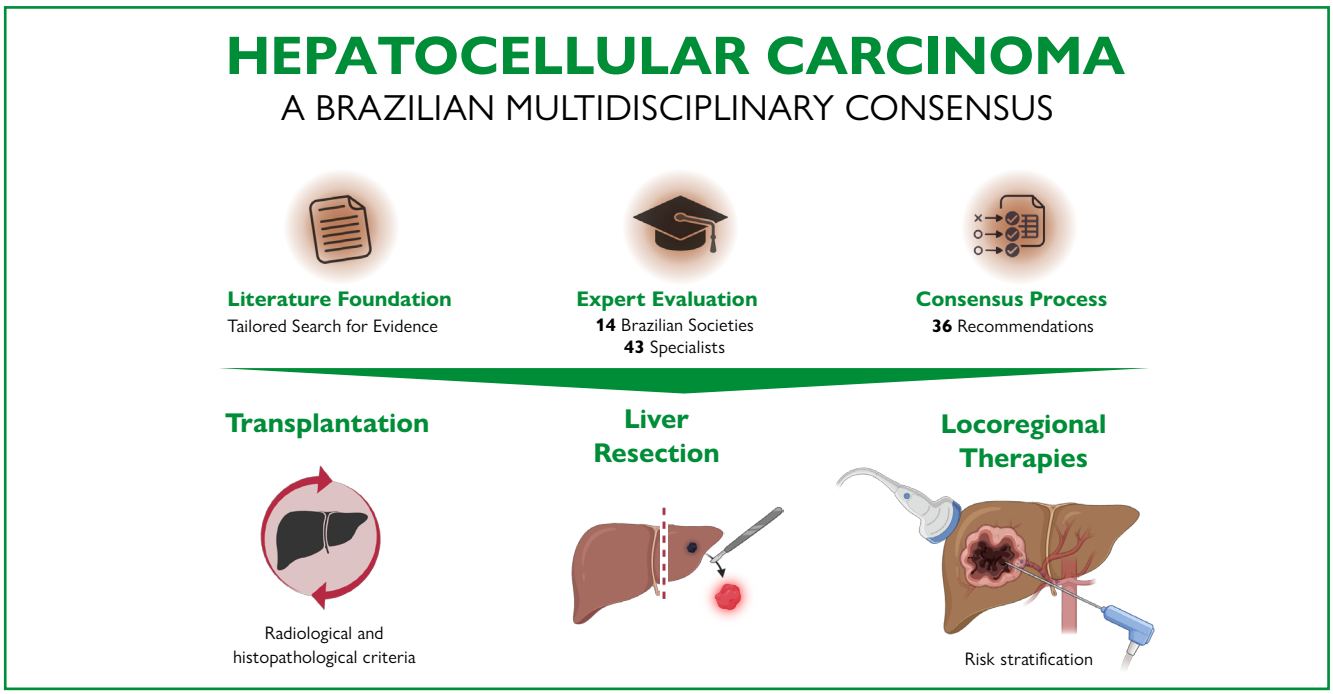

AUTHORS
Felipe José Fernández COIMBRA, André Luís de GODOY, Paulo Henrique de Sousa FERNANDES, Heládio FEITOSA NETO, Rodrigo Nascimento PINHEIRO, Ilka de Fátima Santana Ferreira BOIN, Wellington ANDRAUS, Francisco TUSTUMI, Paulo Cezar Galvão do AMARAL, Carlos Eduardo BRANDÃO MELLO, Alexcia Camila BRAUN, Maria Ignez BRAGHIROLI, Luis César BREDT, Carla CAPARROZ, Flair José CARRILHO, Guilherme Moura CUNHA, Alessandro Landskron DINIZ, Daniel Neves FORTE, José Huygens Parente GARCIA, Tércio GENZINI, Mauro Monteiro CORREIA, Cássio Virgílio Cavalcante de OLIVEIRA, Antonio Nocchi KALIL, Agnaldo Soares LIMA, Guilherme Lopes Pinheiro MARTINS, Cristina Melo ROCHA, Marcos Roberto de MENEZES, Joaquim Maurício da MOTTA-LEAL-FILHO, Munir MURAD JÚNIOR, Renata D'Alpino PEIXOTO, Rafael Soares PINHEIRO, Marcelo Bruno REZENDE, Héber Salvador de Castro RIBEIRO, Mario Rino MARTINS, Duilio Reis da ROCHA FILHO, Arthur Accioly ROSA, Luiz Arnaldo SZUTAN, Orlando Jorge Martins TORRES, Luiz Augusto Carneiro D'ALBUQUERQUE, Ângelo Alves de MATTOS, Anelisa Kruschewsky COUTINHO, Paulo HERMAN, Alexandre Ferreira OLIVEIRA

CORRESPONDENCE
Felipe José Fernández Coimbra. Email: felipe.coimbra@accamargo.org.br

HOW TO CITE THIS ARTICLE
How to cite this article: Coimbra FJF, Godoy AL, Fernandes PHS, Feitosa Neto H, Pinheiro RN, Boin IFSF, et al. Liver resection, transplantation, and local therapies for hepatocellular carcinoma: a Brazilian multidisciplinary consensus. ABCD Arq Bras Cir Dig. 2026;39:e1986. https://doi.org/10.1590/0102-672020260000057e1986.

ARTICLE HIGHLIGHTS

- This third article of the four-part Brazilian multidisciplinary consensus focuses on curative and locoregional treatment strategies for hepatocellular carcinoma.
- It provides evidence-based recommendations on liver resection, liver transplantation, and local therapies.
- The consensus combines current scientific evidence with multidisciplinary expertise to support individualized therapeutic decision-making.

CENTRAL MESSAGE

Surgical and locoregional therapies remain central pillars in hepatocellular carcinoma management and offer the greatest potential for long-term survival and cure in selected patients. This multidisciplinary consensus integrates the best available evidence with expert clinical judgment to guide appropriate patient selection and treatment allocation among liver resection, transplantation, and local therapies.

PERSPECTIVES

This consensus provides practical, clinically oriented guidance to optimize the use of surgical and locoregional treatments for hepatocellular carcinoma in real-world practice. By reinforcing the importance of careful patient selection, multidisciplinary discussion, and individualized therapeutic strategies, the recommendations aim to improve treatment outcomes and reduce inappropriate interventions across diverse healthcare settings.

CC BY

ABCD Arq Bras Cir Dig
2026;39:e1986
https://doi.org/10.1590/0102-672020260000057e1986

REVIEW ARTICLE - POSITION PAPER

Liver resection, transplantation, and local therapies for hepatocellular carcinoma: a Brazilian multidisciplinary consensus

Ressecção hepática, transplante e terapias locais para carcinoma hepatocelular: um consenso multidisciplinar brasileiro

Felipe José Fernández COIMBRA[1], André Luís de GODOY[1], Paulo Henrique de Sousa FERNANDES[2], Heládio FEITOSA NETO[3], Rodrigo Nascimento PINHEIRO[4], Ilka de Fátima Santana Ferreira BOIN[5], Wellington ANDRAUS[6], Francisco TUSTUMI[6], Paulo Cezar Galvão do AMARAL[7], Carlos Eduardo BRANDÃO MELLO[8], Alexcia Camila BRAUN[1], Maria Ignez BRAGHIROLI[9], Luis César BREDT[10], Carla CAPARROZ[11], Flair José CARRILHO[6], Guilherme Moura CUNHA[12], Alessandro Landskron DINIZ[1], Daniel Neves FORTE[13], José Huygens Parente GARCIA[14], Tércio GENZINI[15], Mauro Monteiro CORREIA[16], Cássio Virgílio Cavalcante de OLIVEIRA[17], Antonio Nocchi KALIL[18], Agnaldo Soares LIMA[19], Guilherme Lopes Pinheiro MARTINS[20], Cristina Melo ROCHA[21], Marcos Roberto de MENEZES[22], Joaquim Maurício da MOTTA-LEAL-FILHO[22], Munir MURAD JÚNIOR[23], Renata D'Alpino PEIXOTO[24], Rafael Soares PINHEIRO[6], Marcelo Bruno REZENDE[25], Héber Salvador de Castro RIBEIRO[1], Mario Rino MARTINS[26], Duilio Reis da ROCHA FILHO[27], Arthur Accioly ROSA[28], Luiz Arnaldo SZUTAN[29], Orlando Jorge Martins TORRES[30], Luiz Augusto Carneiro D'ALBUQUERQUE[6], Ângelo Alves de MATTOS[31], Anelisa Kruschewsky COUTINHO[32], Paulo HERMAN[6], Alexandre Ferreira OLIVEIRA[33]

ABSTRACT

Background: Curative treatment for hepatocellular carcinoma is limited to strategies that achieve complete tumor eradication, primarily liver resection, liver transplantation, and locoregional therapies. However, therapeutic decision-making is complex and must balance tumor burden, liver function, patient characteristics, and resource availability. **Aims:** To develop multidisciplinary, evidence-based recommendations for the use of surgical and locoregional therapies in hepatocellular carcinoma management. **Methods:** The Brazilian Society of Surgical Oncology coordinated this consensus in collaboration with 13 additional Brazilian medical societies. A scientific steering committee identified clinically relevant questions addressing indications, patient selection, technical considerations, and outcomes related to liver resection, liver transplantation, and locoregional therapies. **Results:** A total of 36 clinical questions reached consensus, generating evidence-based recommendations across three major domains: liver resection, including criteria for resectability, assessment of liver functional reserve, and strategies to expand surgical candidacy; liver transplantation, addressing selection criteria, expanded eligibility concepts, donor source considerations, and the role of bridging and downstaging therapies; and locoregional therapies, encompassing ablative and intra-arterial treatments, their indications as definitive, bridging, or alternative strategies, and their integration within multidisciplinary care pathways. **Conclusions:** This multidisciplinary consensus provides structured, evidence-based guidance on the use of liver resection, liver transplantation, and locoregional therapies in hepatocellular carcinoma management. By addressing key clinical questions about patient selection, therapeutic indications, and integration of curative and locoregional strategies, these recommendations aim to support consistent, informed decision-making in daily clinical practice and to optimize outcomes for patients eligible for potentially curative treatment.

Headings: Carcinoma, Hepatocellular. Consensus. Guidelines as Topic. Liver Transplantation. Hepatectomy. Ablation Techniques.

[1]A.C. Camargo Cancer Center, Abdominal Surgery, HPB & Upper GI Oncology Reference Center, Department of Surgical Oncology – São Paulo (SP), Brazil.
[2]Universidade Federal de Uberlândia, Department of Surgical Oncology – Uberlândia (MG), Brazil.
[3]Instituto do Câncer do Ceará, Department of Surgical Oncology – Fortaleza (CE), Brazil.
[4]Hospital de Base do Distrito Federal, Department of Surgical Oncology – Brasília (DF), Brazil.
[5]Universidade Estadual de Campinas, Department of Surgery – Campinas (SP), Brazil.
[6]Universidade de São Paulo, Department of Gastroenterology – São Paulo (SP), Brazil.
[7]São Rafael Hospital/Rede D'Or Hospital Group, São Luiz, Department of Surgery of the Upper Digestive System – Salvador (BA), Brazil.
[8]Universidade Federal do Estado do Rio de Janeiro, Department of Internal Medicine – Rio de Janeiro (RJ), Brazil.
[9]Instituto do Câncer do Estado de São Paulo, Department of Oncology – São Paulo (SP), Brazil.
[10]Universidade Estadual do Oeste do Paraná, Department of Surgical Oncology and Hepatobiliary Surgery – Cascavel (PR), Brazil.
[11]Hospital Beneficência Portuguesa de São Paulo, Department of Radiology – São Paulo (SP), Brazil.
[12]University of Washington, Department of Radiology – Seattle, United States of America.
[13]Universidade de São Paulo, Emergency Department – São Paulo (SP), Brazil.
[14]Universidade Federal do Ceará, Walter Cantídio University Hospital, Liver Transplant Unit, Department of Surgery – Fortaleza (CE), Brazil.
[15]Leforte Hospital, Pancreas and Kidney Transplant Program – São Paulo (SP), Brazil.
[16]Instituto Nacional do Câncer, Department of Abdominopelvic Surgery – Rio de Janeiro (RJ), Brazil.
[17]Universidade Federal da Paraíba, Department of Surgery – João Pessoa (PB), Brazil.
[18]Irmandade Santa Casa de Misericórdia de Porto Alegre, Department of Hepato-Biliary-Pancreatic Surgery and Liver Transplantation – Porto Alegre (RS), Brazil.
[19]Universidade Federal de Minas Gerais, Department of Surgery – Belo Horizonte (MG), Brazil.
[20]Instituto do Câncer do Estado de São Paulo, Department of Radiology – São Paulo (SP), Brazil.
[21]Universidade Federal do Amazonas, Department of Gastroenterology – Manaus (AM), Brazil.
[22]Universidade de São Paulo, Department of Radiology – São Paulo (SP), Brazil.
[23]Universidade Federal de Minas Gerais, Department of Oncology – Belo Horizonte (MG), Brazil.
[24]University of British Columbia, Department of Medical Oncology – Vancouver, Canada.
[25]Hospital Israelita Albert Einstein, Department of Health Sciences – São Paulo (SP), Brazil.
[26]Hospital de Câncer de Pernambuco, Department of Oncological Surgery – Recife (PE), Brazil.
[27]Universidade Federal do Ceará, Department of Oncology – Fortaleza (CE), Brazil.
[28]Oncoclínicas Salvador and Hospital Santa Izabel, Department of Radiation Oncology – Salvador (BA), Brazil.
[29]Faculdade de Ciências Médicas da Santa Casa de São Paulo, Department of Surgery – São Paulo (SP), Brazil
[30]Universidade Federal do Maranhão, Department of Gastrointestinal Surgery – São Luís (MA), Brazil.
[31]Universidade Federal de Ciências da Saúde de Porto Alegre, Department of Gastroenterology and Hepatology – Porto Alegre (RS), Brazil.
[32]Rede Mater Dei, Department of Oncology – Salvador (BA), Brazil.
[33]Universidade Federal de Juiz de Fora, Department of Surgery – Juiz de Fora (MG), Brazil.
Correspondence: Felipe José Fernández Coimbra. Email: felipe.coimbra@accamargo.org.br
Financial source: None.
Conflicts of interests: None.
Received: 05/23/2026. Accepted: 06/02/2026.

Editor: Nelson Adami Andreollo

How to cite this article: Coimbra FJF, Godoy AL, Fernandes PHS, Feitosa Neto H, Pinheiro RN, Boin IFSF, et al. Liver resection, transplantation, and local therapies for hepatocellular carcinoma: a Brazilian multidisciplinary consensus. ABCD Arq Bras Cir Dig. 2026;39:e1986. https://doi.org/10.1590/0102-672020260000057e1986.

CC BY

RESUMO

Racional: O tratamento curativo do carcinoma hepatocelular (CHC) limita-se a estratégias que visam à erradicação completa do tumor, principalmente a ressecção hepática, o transplante hepático e as terapias locorregionais. No entanto, a tomada de decisão terapêutica é complexa e deve equilibrar a carga tumoral, a função hepática, as características do paciente e a disponibilidade de recursos. **Objetivos:** Desenvolver recomendações multidisciplinares, baseadas em evidências, para o uso de terapias cirúrgicas e locorregionais no manejo do CHC. **Métodos:** Este consenso foi coordenado pela Sociedade Brasileira de Cirurgia Oncológica em colaboração com outras 13 sociedades médicas brasileiras. Um comitê científico diretivo identificou questões clinicamente relevantes, abrangendo indicações, seleção de pacientes, considerações técnicas e desfechos relacionados à ressecção hepática, ao transplante hepático e às terapias locorregionais. **Resultados:** Um total de 36 questões clínicas alcançaram consenso, gerando recomendações baseadas em evidências em três domínios principais: ressecção hepática, incluindo critérios de ressecabilidade, avaliação da reserva funcional hepática e estratégias para ampliar a elegibilidade cirúrgica; transplante hepático, abordando critérios de seleção, conceitos de elegibilidade expandidos, considerações sobre a fonte do doador e o papel das terapias de ponte; e terapias locorregionais, abrangendo tratamentos ablativos e intra-arteriais, suas indicações como estratégias definitivas, de ponte ou alternativas e sua integração em vias de atendimento multidisciplinares. **Conclusões:** Este consenso multidisciplinar fornece orientações estruturadas e baseadas em evidências sobre o uso de ressecção hepática, transplante hepático e terapias locorregionais no tratamento do CHC. Ao abordar questões clínicas importantes relacionadas à seleção de pacientes, indicações terapêuticas e integração de estratégias curativas e locorregionais, essas recomendações visam apoiar a tomada de decisões consistentes e informadas na prática clínica diária e otimizar os resultados para pacientes elegíveis para tratamento potencialmente curativo.

Descritores: Carcinoma Hepatocelular. Consenso. Guias como Assunto. Transplante de Fígado. Hepatectomia. Técnicas de Ablação.

INTRODUCTION

Hepatocellular carcinoma (HCC) is one of the most common malignancies worldwide and one of the leading causes of cancer-related mortality, mainly due to its frequent diagnosis at advanced stages and its close association with chronic liver disease and cirrhosis[31]. Despite this unfavorable global prognosis, patients diagnosed at early stages may achieve long-term survival when treated with curative-intent therapies. Notably, the only treatment strategies with curative potential for HCC include achieving complete eradication of tumor cells, either through surgical removal or local destruction of viable tumor cells[21,238].

Curative treatment of HCC is therefore fundamentally based on liver resection, liver transplantation, or local ablative therapies. Surgical resection represents a cornerstone of treatment for patients with preserved liver function and resectable disease, offering favorable long-term outcomes when carefully selected. However, resectability is not determined by tumor characteristics alone; it critically depends on the underlying liver functional reserve and the presence or absence of portal hypertension, which are key predictors of postoperative liver failure and long-term survival[180].

Liver transplantation occupies a unique position in the management of HCC, as it simultaneously treats the tumor and the underlying liver disease, thereby reducing both recurrence risk and the likelihood of *de novo* carcinogenesis in a chronic liver disease. Transplant eligibility has traditionally been guided by the Milan criteria, which select patients with limited tumor burden and have been associated with excellent post-transplant survival and low recurrence rates[147]. Over time, expanded criteria incorporating tumor size, number, and biological markers have been proposed to increase access to transplantation without compromising outcomes[109].

However, liver transplantation for HCC raises complex considerations related to organ availability and allocation. In many regions, the use of deceased-donor grafts for patients with preserved liver function but oncological indications must be carefully balanced against broader transplant waitlist priorities, as allocating a scarce graft to an HCC patient may affect access for other candidates with end-stage liver disease. In this context, living-donor liver transplantation has emerged as an alternative strategy in selected settings, allowing timely treatment of HCC while partially mitigating constraints related to deceased-donor allocation. Nevertheless, living-donor transplantation introduces distinct ethical and clinical challenges, as it exposes a healthy donor to a non-negligible surgical risk and requires rigorous risk–benefit assessment for both donor and recipient[27].

At the other end of the therapeutic spectrum, locoregional therapies have lower procedural risk and play an important role in HCC management. These treatments may be used as definitive therapy for selected early-stage tumors, as bridging or downstaging strategies before liver transplantation, or as alternatives when surgical treatment is not feasible. Locoregional therapies include a heterogeneous group of techniques aimed at achieving tumor control through direct local intervention. Ablative modalities include percutaneous ethanol injection (PEI), radiofrequency ablation (RFA), microwave ablation (MWA), and radiotherapy, which induce tumor necrosis through chemical, thermal, or radiation-based mechanisms. In contrast, intra-arterial therapies use the preferential blood supply artery in HCC to deliver embolic agents, chemotherapeutic drugs, or radioactive particles directly to the tumor, including transarterial chemoembolization (TACE) and transarterial radioembolization (TARE)[21,230,238].

In this evolving therapeutic scenario, identifying optimal strategies for liver resection, transplantation, and locoregional therapies is essential to improve outcomes for patients with HCC. This Brazilian multidisciplinary consensus, developed by experts in surgical oncology, hepatology, radiology, hepatopancreatobiliary surgery, liver transplantation, medical oncology, interventional radiology, radiotherapy, and palliative care, addresses the most relevant clinical questions encountered in daily practice. By synthesizing available evidence, this document aims to guide therapeutic decision-making, clarify transplant allocation considerations, and contextualize access to locoregional treatments, providing a structured framework for the management of HCC patients eligible for curative or locoregional interventions.

METHODS

This document is part of a coordinated series of Brazilian multidisciplinary consensus publications on HCC, led by

the Brazilian Society of Surgical Oncology in partnership with 13 national medical societies. The societies involved in this phase of the consensus included specialists in surgical oncology, hepatology, clinical oncology, hepatopancreatobiliary surgery, radiology, interventional radiology, liver transplantation, pathology, gastroenterology, radiation oncology, and palliative care, ensuring broad representation of expertise relevant to managing advanced HCC.

The methodological framework used in this article follows the same consensus development process previously detailed by Coimbra et al.[41], which outlines the overarching structure for all phases of the consensus initiative. Briefly, a scientific steering committee identified and prioritized clinically relevant questions regarding liver resection, liver transplantation, and locoregional treatments. These questions were discussed and refined during multidisciplinary meetings.

A focused literature review informed the evidence underpinning each recommendation. The appraisal process distinguished the robustness of the available evidence, classified as high, moderate, or low, and the corresponding recommendation strength, defined as strong or weak.

RESULTS

In this phase of the Brazilian national consensus on HCC, 43 experts from multiple medical disciplines actively contributed to developing recommendations. The panel developed 36 evidence-based consensus statements addressing the full spectrum of liver resection, liver transplantation, and locoregional therapies. These statements reflect multidisciplinary agreement on key clinical questions for HCC management and are intended to support consistent, informed decision-making in daily clinical practice. Table 1 summarizes the final recommendations.

Which HCC patients should be considered optimal candidates for hepatic resection?

Hepatic resection is a potentially curative treatment for patients with early-stage HCC and preserved liver function. According to the main Western guidelines—Barcelona Clinic Liver Cancer (BCLC), European Association for the Study of the Liver (EASL), and American Association for the Study of Liver Diseases (AASLD) — surgical resection should be considered for ideal candidates, defined as those with a single lesion without macrovascular invasion, preserved liver function (Child–Pugh A), no clinically significant portal hypertension (normal bilirubin, platelet count>100,000/mm³, absence of ascites or esophageal varices), and good performance status (Eastern Cooperative Oncology Group (ECOG) 0)[62,64,143,183]. In these selected patients, liver resection is associated with excellent outcomes, with reported five-year overall survival rates reaching up to 70%[48,211].

However, population-based and real-world data indicate that many patients undergoing resection do not meet these ideal criteria. The BRIDGE study, a large, global, longitudinal cohort of 8,656 patients from 42 centers in Asia-Pacific, Europe, and North America, found that only 10% of patients with HCC were ideal candidates for resection. Despite this, two-thirds of patients who underwent surgery were classified as non-ideal according to the BCLC guidelines. The global five-year survival rate was 35% in the resected population, whereas ideal candidates (BCLC 0–A) demonstrated a significantly higher five-year survival rate of 65%[168].

Known preoperative risk factors for recurrence after resection include macrovascular and microvascular invasion, multifocal tumors, satellite lesions, and elevated alpha-fetoprotein (AFP) levels[128,213]. These prognostic features should be considered during surgical planning and follow-up.

Recommendation 1: Patients with good performance status (ECOG 0), preserved liver function (Child–Pugh A, Model for End-Stage Liver Disease (MELD) <10, bilirubin <1 mg/dL), absence of clinically significant portal hypertension (no esophageal varices, ascites, or splenomegaly, platelets >100,000/mm³, or hepatic venous pressure gradient <10 mmHg), a single tumor without vascular invasion, and an adequate future liver remnant should be considered candidates for hepatic resection.

Evidence Level: High

Recommendation Grade: Strong

How should curative treatment be selected in patients with HCC smaller than 2 cm and preserved liver function?

Patients with HCC smaller than 2 cm are classified as BCLC-0 (very early stage), a group in which curative-intent treatment is feasible with either surgical resection or percutaneous ablation[183]. Comparative studies have shown similar long-term outcomes between these approaches in carefully selected patients with preserved liver function, with comparable overall survival and disease-free survival. RFA has been associated with lower procedural morbidity, shorter hospital stay, and lower overall costs when compared with surgical resection[81,183,184].

Tumor location is an important determinant in treatment planning. Centrally located tumors may favor an ablative approach to preserve hepatic parenchyma, although proximity to major vascular or biliary structures can limit the safety and effectiveness of RFA[207]. Lesions adjacent to large vessels, extrahepatic organs, or the liver capsule may pose technical challenges and are often considered relative contraindications to thermal ablation due to the risk of incomplete treatment or thermal injury. MWA has emerged as an alternative thermal technique with promising results, potentially reducing the heat sink effect and enabling more predictable ablation zones in selected cases[85,220].

Lesion depth and relationship to surrounding structures also influence treatment selection. Deep parenchymal lesions are frequently amenable to percutaneous ablation, particularly in patients with significant comorbidities who may not tolerate surgery. Conversely, subcapsular or exophytic tumors and lesions located near major vascular or biliary structures may be more safely addressed with surgical resection, as direct visualization allows better control of margins and adjacent anatomy[64,98,112].

When neither resection nor thermal ablation can be safely performed or is not technically feasible, PEI may be considered for tumors up to 2 cm. Although PEI has largely been replaced by thermal ablation because RFA and MWA have higher rates of local tumor control, it remains an option in selected situations where other modalities are unavailable or contraindicated[133,183].

Table 1. List of recommendations with their respective evidence level and recommendation grade.

	Recommendation	Evidence level	Recommendation grade
1	Patients with good performance status (ECOG 0), preserved liver function (Child–Pugh A, MELD<10, bilirubin<1 mg/dL), absence of clinically significant portal hypertension (no esophageal varices, ascites, or splenomegaly, platelets>100,000/mm^3, or hepatic venous pressure gradient<10 mmHg), a single tumor without vascular invasion, and an adequate future liver remnant should be considered candidates for hepatic resection.	High	Strong
2	In patients with HCC smaller than 2 cm and well-preserved liver function, both surgical resection and percutaneous ablation can be recommended, and may be used interchangeably or in combination according to comorbidities, tumor location, tumor number, and technical feasibility. Percutaneous ethanol injection may also be considered as an alternative.	High	Strong
3	In patients with HCC and preserved liver function, hepatic resection may be considered in the presence of mild portal hypertension, defined by small-caliber esophageal varices and a platelet count above 100,000/mm^3, provided minor resection of up to two segments is planned and preferably performed using a minimally invasive approach.	Moderate	Strong
4	In patients with HCC and Child–Pugh B liver function who are not eligible for liver transplantation, hepatic resection may be cautiously considered after multidisciplinary evaluation, preferably limited to minor resections or enucleations in favorable locations and performed using a minimally invasive approach.	Low	Weak
5	Hepatic resection should be avoided in patients with HCC and a MELD score of 10 or higher.	Moderate	Strong
6	HCC location should be systematically assessed because it determines the extent of resection and surgical risk. Evaluation must include the anatomical relationships of the lesion and, when indicated, total liver volume and future liver remnant volumetry.	Low	Strong
7	Thrombocytopenia alone is not an absolute contraindication to hepatic resection. However, platelet counts below 100,000/mm^3 indicate increased risk of post-hepatectomy liver failure and perioperative mortality and must be considered together with liver function and the planned extent of resection when selecting patients for surgery.	High	Strong
8	In HCC patients with vascular invasion who achieve disease control with systemic and/or locoregional therapy, hepatic resection, including complex procedures with vascular resection, may be considered when liver function is preserved, and an adequate future liver remnant can be ensured.	Moderate	Strong
9	In selected patients with multinodular HCC (BCLC B), hepatic resection may be considered when disease burden is limited, preferably in patients meeting the Up-to-Seven criteria, alpha-fetoprotein≤400 ng/mL, preserved liver function (Child–Pugh A), absence of clinically significant portal hypertension, and an adequate future liver remnant.	Moderate	Weak
10	Assessment of liver function and portal hypertension should be incorporated into surgical decision-making for HCC, and a future liver remnant of approximately 30% of total liver volume is required in patients with normal liver parenchyma, whereas at least 40–50% should be preserved in patients with cirrhosis.	High	Strong
11	A minimally invasive approach is preferred for minor resections in favorable segments, including selected patients with cirrhosis and portal hypertension. Minimally invasive complex procedures, particularly major hepatectomies and resections of the posterosuperior segments, should be performed only by teams with advanced expertise in hepatobiliary and minimally invasive liver surgery.	Moderate	Strong
12	Tumor size alone should not be used to contraindicate hepatic resection in HCC, as there is no evidence-based cutoff beyond which surgery is ineffective, and resection may be considered in selected patients based on tumor biology and liver functional reserve.	Moderate	Weak
13	No serum alpha-fetoprotein value contraindicates hepatic resection in HCC, although elevated alpha-fetoprotein levels are associated with more aggressive tumor biology and worse prognosis, and should be considered in preoperative risk stratification.	Moderate	Strong
14	In HCC patients with an insufficient future liver remnant, a sequential strategy of transarterial chemoembolization followed by portal vein embolization should be considered, as it promotes greater liver hypertrophy and leads to better resectability, overall survival, and disease-free survival than portal vein embolization alone.	Moderate	Strong
15	Anatomic resection should be preferred in HCC when liver function is preserved and the procedure is technically feasible, particularly for tumors between 2 and 5 cm; non-anatomic resection should be favored for ≤2 cm lesions or when parenchymal preservation is critical, including in patients with borderline liver function, tumors larger than 5 cm, or multifocal disease involving different segments.	Moderate	Weak
16	At present, there is no evidence to support the routine use of neoadjuvant systemic therapy before hepatic resection in HCC.	Low	Weak
17	There is currently insufficient evidence to support the routine use of adjuvant therapy after surgical resection or ablation for HCC.	High	Weak
18	For patients with HCC within the Milan criteria, hepatic resection should generally be avoided in the presence of clinically significant portal hypertension, impaired liver function beyond Child–Pugh A/B7, or evidence of clinically relevant hepatic decompensation. Resection is also not recommended when the procedure would require a major hepatectomy (>2 segments) in cirrhotic patients or when multifocal tumors involve different hepatic segments, situations in which liver transplantation should be considered the preferred curative strategy.	Moderate	Strong
19	In patients with a single HCC measuring 2–5 cm and preserved liver function (Child–Pugh A/B7), hepatic resection should be the preferred first-line treatment when there is no clinically significant portal hypertension. Limited hepatic resection (up to two segments) may be considered in selected cirrhotic patients with mild portal hypertension and preserved liver function. In the presence of clinically significant portal hypertension, liver transplantation should be considered the preferred curative strategy. For patients initially treated with resection, liver transplantation may be considered as a salvage option in cases of tumor recurrence, provided transplant criteria are still met.	High	Strong

It continues;;;

CC BY

Table 1. Continuation.

	Recommendation	Evidence level	Recommendation grade
20	In Brazil, liver transplantation is recommended as a first-line treatment option for patients with HCC≥2 cm associated with cirrhosis, within Milan criteria, with alpha-fetoprotein≤1,000 ng/mL, including after locoregional therapy, who are not candidates for resection, and who have no contraindication to transplantation. In addition, for patients with HCC≥2 cm within Milan criteria who undergo resection, liver transplantation may be prioritized in cases of recurrence within 2 years that remains within Milan criteria, with MELD retroactive to the date of resection, or in cases of severe postoperative liver failure, with MELD 40 if reported by postoperative day 15 and MELD 30 thereafter, valid for up to 60 days and subject to review by the National Technical Chamber.	Moderate	Weak
21	The Milan criteria should remain the reference standard for liver transplantation for HCC in Brazil. Patients who do not meet these criteria may be considered for transplantation only after successful downstaging to within the Milan criteria, in the absence of macrovascular invasion or extrahepatic disease.	Moderate	Weak
22	Living-donor liver transplantation may be considered for selected patients with HCC, particularly when deceased-donor access is limited, provided there is favorable tumor biology and no macrovascular invasion or extrahepatic disease.	Moderate	Weak
23	In HCC patients listed for liver transplantation within the Milan criteria, bridge therapy should be considered to reduce the risk of tumor progression and waitlist dropout, and no specific locoregional modality should be preferred over another, with the choice guided by tumor characteristics, technical feasibility, and local expertise.	Moderate	Weak
24	Advanced age alone should not contraindicate liver transplantation in HCC, and candidate selection should be based on physiological status, comorbidities, and functional reserve rather than age.	Low	Strong
25	A history of treated extrahepatic malignancy does not in itself contraindicate liver transplantation in HCC, but listing should be considered only after completion of cancer therapy, an adequate disease-free interval, and multidisciplinary assessment of recurrence risk and expected post-transplant survival.	Low	Weak
26	High exposure to calcineurin inhibitors should be avoided after liver transplantation for HCC, and mTOR-based immunosuppression may be considered as a strategy to potentially reduce the risk of tumor recurrence.	Low	Weak
27	In patients with intrahepatic recurrence of HCC after liver transplantation, surgical resection or other locoregional therapies should be considered whenever feasible, and systemic therapy should be used when locoregional treatments are not possible.	Low	Strong
28	Transarterial chemoembolization is the standard treatment for intermediate-stage HCC (BCLC B) in patients with non-diffuse intrahepatic disease and suitable arterial anatomy. Transarterial chemoembolization with drug-eluting beads may be preferred to reduce systemic toxicity, with survival comparable to that of conventional transarterial chemoembolization.	High	Strong
29	Transarterial radioembolization is an alternative intra-arterial therapy to transarterial chemoembolization in patients with BCLC B HCC with non-diffuse disease and may be considered in patients with portal vein tumor thrombosis (BCLC C), particularly when thrombosis involves lobar or segmental branches, provided there is preserved liver function and no clinically significant hyperbilirubinemia.	High	Weak
30	Radiofrequency ablation should be used for early-stage HCC patients with preserved liver function who are not ideal candidates for surgical resection or liver transplantation, particularly for tumors up to 3 cm located away from major vessels, bile ducts, and adjacent organs, with the best outcomes observed in lesions≤2 cm.	High	Strong
31	In patients with HCC being managed with locoregional therapy, particularly those with tumors between 3 and 5 cm who are not candidates for surgical resection or transplantation, the combination of transarterial chemoembolization followed by radiofrequency ablation may be considered.	Moderate	Weak
32	Percutaneous ethanol injection may be used for HCC up to 2 cm when surgical resection or thermal ablation are not feasible or not available, particularly in tumors located close to bile ducts or hollow viscera.	High	Strong
33	Microwave ablation yields outcomes comparable to radiofrequency ablation for HCC lesions up to 3 cm and may be preferred for tumors up to 4 cm or those adjacent to large vessels because of its lower susceptibility to heat-sink effects.	Moderate	Weak
34	Although irreversible electroporation can be used to treat centrally located, unresectable HCC lesions near bile ducts and major vessels, there is currently insufficient evidence to support its routine clinical use.	Low	Weak
35	Combination strategies involving transarterial chemoembolization with lenvatinib-based or immune-based systemic therapy may be considered in selected patients after multidisciplinary evaluation, particularly when the goal is to improve tumor response and progression-free survival, while recognizing the higher risk of treatment-related adverse events and the still-limited mature overall survival data. The addition of immunotherapy to thermal ablation should be considered investigational.	Low	Weak
36	In HCC, external beam radiation therapy may be used as a locoregional treatment in patients who are not candidates for resection, transplantation, or thermal ablation because of comorbidities, limited liver reserve, or unfavorable tumor location, and it may also be used for consolidation after incomplete response following embolization or ablation.	Moderate	Strong

HCC: hepatocellular carcinoma; ECOG: Eastern Cooperative Oncology Group; MELD: Model for End-Stage Liver Disease; BCLC: Barcelona Clinic Liver Cancer.

In Brazil, the current liver transplantation allocation system does not grant a priority MELD exception for HCC lesions smaller than 2 cm. As a result, patients with preserved liver function and very early tumors are generally managed with resection or ablation, while transplantation is usually considered only if the disease progresses to meet accepted transplant criteria.

Recommendation 2: In patients with HCC smaller than 2 cm and well-preserved liver function, both surgical resection and percutaneous ablation can be recommended, and may be used interchangeably or in combination according to comorbidities, tumor location, tumor number, and technical feasibility. PEI may also be considered as an alternative.

Evidence Level: High

Recommendation Grade: Strong

Under what circumstances can hepatic resection be considered for patients with HCC and portal hypertension?

Clinically significant portal hypertension (CSPH) is a well-established predictor of postoperative liver failure and mortality after hepatic resection. CSPH is commonly defined by a hepatic venous pressure gradient (HVPG) greater than 10 mmHg or by indirect clinical markers such as gastroesophageal varices, splenomegaly, ascites, or thrombocytopenia below 100,000/mm³ [15,155,217]. These findings reflect impaired hepatic reserve and increased risk of postoperative decompensation following liver resection.

The risk associated with resection increases with the extent of hepatectomy and with worsening baseline liver function. Patients with MELD scores ≥10 and those undergoing major hepatectomies have substantially higher rates of postoperative hepatic failure[15]. In a large Italian cohort including 543 patients who underwent liver resection for HCC, the combination of portal hypertension and major hepatectomy was associated with postoperative liver failure in approximately 60% of cases and mortality approaching 25%[39].

Multiple systematic reviews of surgical series have also identified portal hypertension as an important negative prognostic factor following hepatic resection, with reduced long-term survival observed between three and five years after surgery[15,166,197]. For this reason, portal hypertension has traditionally been considered a relative contraindication to resection in many treatment algorithms.

More recent data, however, suggest that selected patients with preserved liver function and limited degrees of portal hypertension may still undergo liver resection with acceptable outcomes when careful patient selection is applied. In particular, patients with small-caliber esophageal varices and platelet counts above 100,000/mm³ appear to have lower operative risk with minor hepatectomy. Limiting the extent of resection to two or fewer segments helps preserve functional liver parenchyma and reduces the risk of postoperative liver failure. In addition, minimally invasive approaches have been associated with lower surgical stress and reduced postoperative morbidity in cirrhotic patients undergoing limited liver resections[26,155,211].

Recommendation 3: In patients with HCC and preserved liver function, hepatic resection may be considered in the presence of mild portal hypertension, defined by small-caliber esophageal varices and a platelet count above 100,000/mm³, provided that a minor resection of up to two segments is planned and preferably performed using a minimally invasive approach.

Evidence Level: Moderate

Recommendation Grade: Strong

Can hepatic resection be considered for patients with HCC and Child–Pugh B liver function?

Patients with HCC and Child–Pugh B liver function have reduced hepatic reserve and are at increased risk of postoperative complications, particularly liver failure, after hepatic resection. Several surgical series have shown higher morbidity and lower long-term survival in this population compared with patients undergoing liver transplantation[26,166]. For this reason, impaired liver function has traditionally been considered a major limitation for surgical resection.

Nevertheless, some studies suggest that selected Child–Pugh B patients may tolerate limited hepatic resections when strict selection criteria are applied. In these cases, carefully assessing the balance between oncologic benefit and the risk of postoperative hepatic decompensation is essential, particularly when alternative curative options such as liver transplantation are not feasible[26].

The adoption of minimally invasive liver surgery has also influenced the management of cirrhotic patients. Laparoscopic liver resection is associated with reduced surgical trauma, lower intraoperative blood loss, and less postoperative ascites compared with open surgery. Several surgical series have reported similar perioperative morbidity and mortality between Child–Pugh A and carefully selected Child–Pugh B patients undergoing laparoscopic resection, suggesting that minimally invasive approaches may mitigate some of the risks related to impaired liver function[14,211,222]. These findings indicate that, in highly selected cases with limited disease and favorable tumor location, minor resections performed by minimally invasive techniques may be feasible in patients with Child–Pugh B cirrhosis.

Recommendation 4:

In patients with HCC and Child–Pugh B liver function who are not eligible for liver transplantation, hepatic resection may be cautiously considered after multidisciplinary evaluation, preferably limited to minor resections or enucleations in favorable locations and performed using a minimally invasive approach.

Evidence Level: Low

Recommendation Grade: Weak

In patients with HCC, is there an upper MELD threshold above which hepatic resection is no longer safe?

The MELD score is an established predictor of postoperative liver failure and mortality after hepatic resection. Several retrospective studies have demonstrated a strong association between higher MELD values and increased risk of post-hepatectomy liver failure, reflecting the limited hepatic reserve in patients with advanced liver dysfunction[46,53,91,209]. In surgical series evaluating outcomes after liver resection for HCC, patients with MELD scores below 10 consistently showed lower rates of postoperative liver failure, independent of the extent of hepatic resection[53,222].

CC BY

Despite its prognostic value, MELD should not be interpreted in isolation when evaluating candidacy for hepatic resection. The risk of postoperative liver failure depends on the interaction between baseline liver function, the presence of portal hypertension, and the liver resection magnitude planned. Mazzaferro et al.[147,148] proposed a hierarchical multiparametric model integrating these variables to estimate postoperative risk. In this framework, patients without portal hypertension but with MELD values greater than nine who undergo major hepatectomy present an intermediate risk profile, with reported rates of postoperative liver failure approaching 28.6% and liver-related mortality around 9%[147,148]. These findings highlight the importance of incorporating MELD into a broader assessment of surgical risk rather than relying on a single parameter when evaluating hepatic resection safety in HCC patients.

Recommendation 5: Hepatic resection should be avoided in patients with HCC and a MELD score of 10 or higher.

Evidence Level: Moderate

Recommendation Grade: Strong

How does HCC location impact surgical decision-making?

Tumor location is a major factor in the technical planning of hepatic resection for HCC. Although tumor size and number are more directly related to tumor burden and recurrence risk, location directly affects operative complexity, the amount of liver parenchyma that must be removed, the feasibility of achieving adequate margins, and the risk of injury to major vascular or biliary structures[37].

Despite its practical importance, most major treatment algorithms do not explicitly incorporate tumor location. Current international guidelines are largely based on tumor stage, lesion size and number, liver function, portal hypertension, and performance status, without formally integrating intraparenchymal tumor location into treatment stratification[64,183]. This creates a gap between current guideline-based staging systems and real-world surgical decision-making, in which anatomical location often plays a decisive role.

Lesions near major hepatic veins, Glissonian pedicles, or the hepatic hilum may require more extensive resection than would be expected based on tumor size alone, whereas peripherally located tumors may be amenable to more limited parenchyma-sparing procedures. Tumor location influences the functional consequences of surgery. A small lesion in an unfavorable segment could mean sacrificing a substantial volume of non-tumoral liver, while a larger lesion in a more accessible area may still allow a limited resection. For this reason, anatomical relationships within the liver are closely linked to both surgical risk and postoperative liver reserve. In selected cases, especially when a major hepatectomy is being considered, or when underlying liver disease is present, total liver volume and future liver remnant assessment may provide additional information relevant to operative planning and safety.

Recommendation 6: HCC location should be systematically assessed because it determines the extent of resection and surgical risk. Evaluation must include how the lesion connects to nearby anatomy and, when indicated, total liver volume and future liver remnant volumetry.

Evidence Level: Low

Recommendation Grade: Strong

What are the limits for hepatic resection in HCC patients with thrombocytopenia?

Thrombocytopenia is an important marker of surgical risk in patients with HCC undergoing hepatic resection because it is closely associated with portal hypertension and impaired hepatic reserve.

In a cohort of 2,097 patients, platelet count<100,000/mm³ was the strongest adverse prognostic factor, with an approximately fourfold higher risk of mortality than patients with platelet counts>150,000/mm³ on multivariable analysis. Even platelet counts between 100,000 and 150,000/mm³ were associated with increased mortality, with an approximately 1.8-fold higher risk compared with patients with normal platelet counts[217]. Meyer, in a meta-analysis, found that preoperative thrombocytopenia was a major risk factor for post-hepatectomy liver failure, with a relative risk of 4.57, in both cirrhotic and non-cirrhotic patients[155]. In addition to perioperative risk, thrombocytopenia has been associated with worse oncologic outcomes[165,243].

According to EASL and AASLD guidance, platelet counts≥100,000/mm³ argue against clinically significant portal hypertension, whereas the Baveno criteria use a more conservative threshold of ≥150,000/mm³ in selected patients with chronic liver disease[52,64,89].

Recommendation 7: Thrombocytopenia alone is not an absolute contraindication to hepatic resection. However, platelet counts below 100,000/mm³ indicate increased risk of post-hepatectomy liver failure and perioperative mortality and must be considered together with liver function and the planned extent of resection when selecting patients for surgery.

Evidence Level: High

Recommendation Grade: Strong

In which scenarios can hepatic resection be considered in HCC patients with vascular invasion?

Vascular invasion in HCC, particularly portal vein tumor thrombosis (PVTT), represents a heterogeneous clinical condition in which prognosis depends on the extent of portal involvement, tumor burden, liver function, and patient performance status. The anatomical level of portal invasion is one of the most important prognostic factors and plays a central role in therapeutic decision-making[178,179].

The most widely used classification system is that proposed by the Liver Cancer Study Group of Japan (Figure 1), which stratifies PVTT according to the level of portal involvement: Vp1 (segmental or distal portal branches), Vp2 (second-order portal branches), Vp3 (first-order portal branches involving the right or left portal vein), and Vp4 (main portal trunk or contralateral branch involvement)[199]. Several surgical series have demonstrated a strong correlation between the level of portal invasion and long-term outcomes after resection. In a large systematic review, five-year survival rates after hepatic resection were approximately 45% in patients with distal PVTT, 19% in those with first-order branch involvement, and 14.5% in patients with main portal trunk invasion[79]. Similarly, a Japanese multicenter analysis showed that survival progressively declined with increasing PVTT extent, with median survival of 4.13 years for Vp1 disease and 0.91 years for Vp4 disease in Child–Pugh A patients[108].

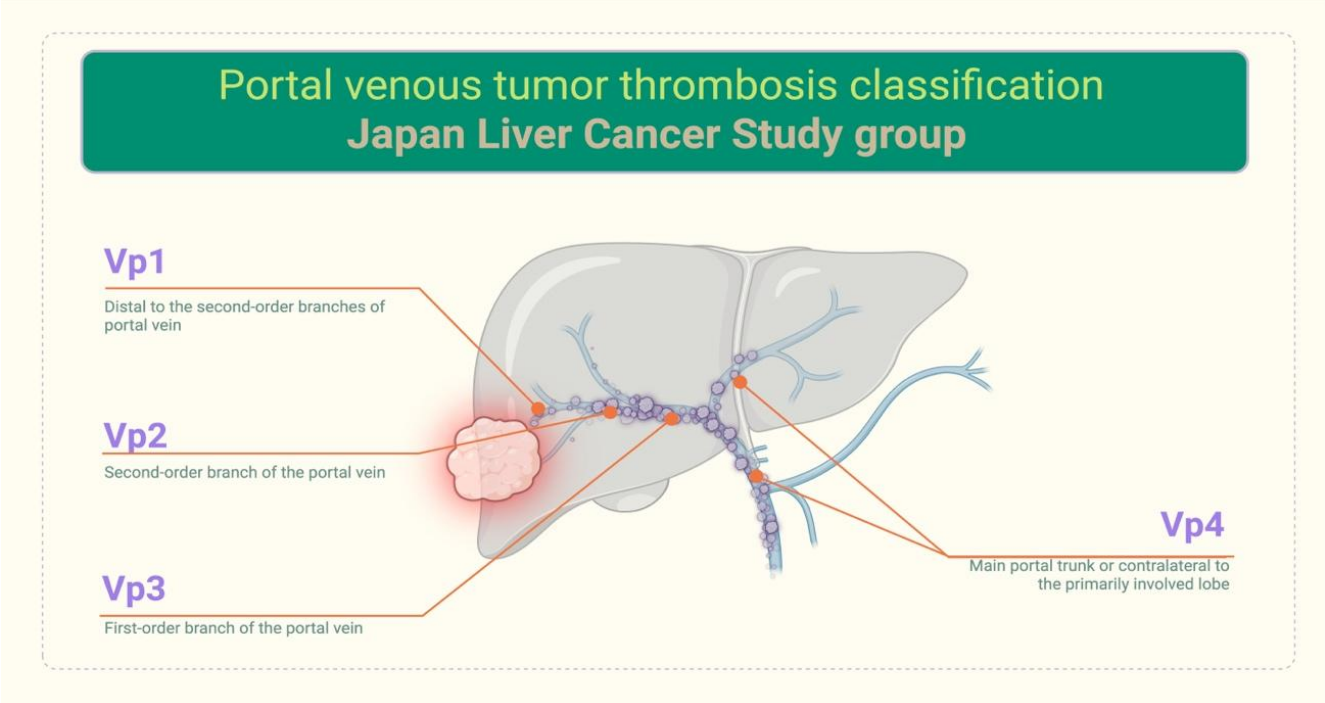

Figure 1. Portal venous tumor thrombosis classification according to the Japan Liver Cancer Study Group.

Recent reports also suggest interpreting vascular invasion within the broader clinical context, including tumor burden and response to prior therapies. In some patients, locoregional or systemic treatments may control the disease, allowing reconsideration of surgical strategies. Multimodal treatment approaches integrating systemic therapy, TACE, TARE, or radiotherapy have therefore been explored in selected patients before surgical resection[101,179,241,244].

Comparative evidence evaluating different treatment strategies for HCC with macroscopic vascular invasion has also been reported. In a systematic review and network meta-analysis including 31 studies, surgical approaches (liver resection or liver transplantation) were associated with improved long-term survival compared with non-surgical treatments. In the network analysis, systemic therapy showed the lowest survival outcomes, whereas liver resection and liver transplantation demonstrated comparable survival benefits. The pooled analysis showed a significantly higher three-year overall survival in the surgical group (transplantation or resection) compared with non-surgical therapies (risk difference 0.12; 95% confidence interval (95%CI) 0.05–0.20), although surgical alternatives were associated with a higher rate of complications (risk difference 0.06; 95%CI 0.00–0.12)[215]. Despite these findings, most data derive from retrospective series and indirect comparisons. No prospective trials have directly compared hepatic resection with systemic therapy or other locoregional modalities in patients with PVTT. Consequently, the survival outcomes reported in surgical cohorts may partly reflect patient selection, particularly the inclusion of individuals with preserved liver function and more favorable tumor biology.

Overall, outcomes after hepatic resection decline markedly as portal invasion becomes more proximal, and the extent of vascular involvement remains a key determinant of prognosis. These data highlight the importance of careful patient selection, detailed anatomical assessment of portal invasion, and multidisciplinary evaluation when considering surgical strategies in HCC with vascular invasion.

Recommendation 8: In HCC patients with vascular invasion who achieve disease control with systemic and/or locoregional therapy, hepatic resection, including complex procedures with vascular resection, may be considered when liver function is preserved, and an adequate future liver remnant can be ensured.

Evidence Level: Moderate

Recommendation Grade: Strong

Can hepatic resection be considered in patients with multifocal HCC (BCLC B)?

The role of hepatic resection in patients with multi-nodular HCC, particularly those beyond Milan criteria, remains controversial. Concerns arise from the higher risk of postoperative complications, increased recurrence rates, and reduced long-term survival observed in patients with more advanced intrahepatic tumor burden[150].

Despite these concerns, several surgical series have reported favorable outcomes with liver resection in carefully selected patients with multi-nodular HCC and preserved liver function. In these studies, surgical treatment was associated with improved survival compared with TACE, which remains the conventional treatment recommended in many Western guidelines for BCLC B disease[79,94,127,218]. A meta-analysis including predominantly Asian cohorts demonstrated superior overall survival in patients undergoing hepatic resection compared with TACE, without a significant increase in postoperative complications or 30-day mortality[127]. Tumor number appears to influence outcomes after surgery. A systematic review reported that five-year survival after resection was substantially higher in patients with up to three nodules (approximately 49%) than in those with four or more nodules (approximately 23%)[79].

More recent multicenter data from specialized hepatobiliary centers, including predominantly Western populations, have also shown encouraging outcomes with resection in selected patients with BCLC B and even BCLC C disease. In

CC BY

this international cohort, overall five-year survival after hepatic resection approached 50%. However, tumor size and the number of nodules significantly impact prognosis. To address this, prognostic stratification based on the "Up-to-Seven" criteria (Figure 2)—defined as the sum of the diameter of the largest tumor (in centimeters) and the total number of tumors not exceeding the value of seven—effectively addresses the interaction between tumor size and number, identifying patients with more favorable outcomes[203]. In this cohort, patients within the Up-to-Seven criteria achieved a five-year survival of 68.4% compared with 46.3% in patients beyond these criteria (p=0.027). In addition, lower preoperative AFP levels (≤400 ng/mL) and achievement of R0 resection were associated with a reduced risk of recurrence[237].

Comparative prospective evidence remains limited, but at least one randomized trial comparing hepatic resection and TACE in patients with multi-nodular HCC demonstrated superior survival in the surgical group[99,237]. Collectively, these data illustrate the marked heterogeneity within intermediate-stage HCC and highlight that selected patients with resectable multi-nodular disease and preserved liver function may achieve meaningful long-term survival after hepatic resection.

Recommendation 9: In selected patients with multi-nodular HCC (BCLC B), hepatic resection may be considered when disease burden is limited, preferably in patients meeting the Up-to-Seven criteria, AFP ≤400 ng/mL, preserved liver function (Child–Pugh A), absence of clinically significant portal hypertension, and an adequate future liver remnant.

Evidence Level: Moderate

Recommendation Grade: Weak

How much future liver remnant is required for safe hepatic resection in HCC?

Adequate future liver remnant (FLR) is one of the most important determinants of safety in hepatic resection for HCC. Preoperative assessment of both the volume and functional capacity of the remnant liver is therefore critical to surgical planning. Post-hepatectomy liver failure (PHLF) remains the most serious complication after liver resection and is associated with substantial postoperative morbidity and mortality. The risk of PHLF is multifactorial, but the volume and functional reserve of the FLR are consistently identified as the main independent predictors of postoperative complications and liver failure[8,26,96].

Volumetric assessment using cross-sectional imaging is widely used to estimate the proportion of the liver that will remain after resection relative to the total liver volume. In patients with normal liver parenchyma, several surgical series have shown that preservation of approximately one-third of the functional total liver volume is generally sufficient to maintain adequate postoperative hepatic function. In contrast, patients with chronic liver disease, fibrosis, or cirrhosis have reduced regenerative capacity and functional reserve, which substantially increases the risk of PHLF following major hepatectomy. Studies evaluating outcomes after major hepatectomy in cirrhotic patients suggest that an FLR of 40%-50% of the total liver volume is associated with safer postoperative outcomes[26,96].

Recommendation 10: Assessment of liver function and portal hypertension should be incorporated into surgical decision-making for HCC, and a future liver remnant of approximately 30% of total liver volume is required in patients with normal liver parenchyma, whereas at least 40–50% should be preserved in patients with cirrhosis.

Evidence Level: High

Recommendation Grade: Strong

What is the role of minimally invasive surgery in hepatic resection for HCC?

Over the past decade, minimally invasive liver surgery (MILS), including laparoscopic and robotic approaches, has been increasingly adopted for the treatment of HCC. Accumulating evidence has established the safety and feasibility of laparoscopic hepatectomy, particularly for minor resections[3,204]. Current practice supports its use mainly in lesions located in the anterolateral segments (segments 2, 3, 4a, 5, and 6), which are technically more accessible and associated with more consistent outcomes[64].

With growing experience, MILS has also been extended to more complex procedures. Specialized centers have performed major hepatectomies and resections involving posterosuperior segments with acceptable outcomes, although these procedures remain technically demanding and are associated with a longer learning curve[38,158]. Multiple factors influence the difficulty of MILS, including tumor size and location, proximity to major vascular structures, extent of resection, and underlying liver function. Several scoring systems have been developed to stratify procedural complexity and support safe implementation[13,25,158].

Although randomized controlled trials comparing MILS and open hepatectomy for HCC are lacking, a large body of evidence from surgical series, systematic reviews, and meta-analyses has consistently demonstrated perioperative advantages associated with minimally invasive approaches. These include reduced intraoperative blood loss, lower transfusion rates, decreased incidence of postoperative ascites and liver dysfunction, and shorter hospital stay, while maintaining comparable oncologic outcomes and overall survival[37,68,118,212].

These benefits appear particularly relevant in patients with chronic liver disease. Reduced abdominal wall trauma, limited liver mobilization, preservation of collateral circulation, and a lower inflammatory response may contribute to improved postoperative recovery in cirrhotic patients. Emerging data suggest that patients with cirrhosis and portal hypertension may better tolerate liver resection when performed using minimally invasive techniques[37,212,229].

Minimally invasive approaches may also have implications for patients who can be candidates for liver transplantation after recurrence. Reduced formation of intra-abdominal adhesions after laparoscopic resection has been associated with easier subsequent transplantation, potentially reducing operative time, blood loss, and transfusion requirements[68].

Robotic liver surgery has expanded minimally invasive options, particularly in technically challenging scenarios. The robotic platform may facilitate dissection and suturing, improve ergonomics, and enhance access to posterosuperior segments, which are traditionally harder to reach laparoscopically. Early series suggest that robotic hepatectomy may allow safe performance of complex resections, including major hepatectomies, although high-quality comparative data remain limited[72,160,226,227].

CC BY

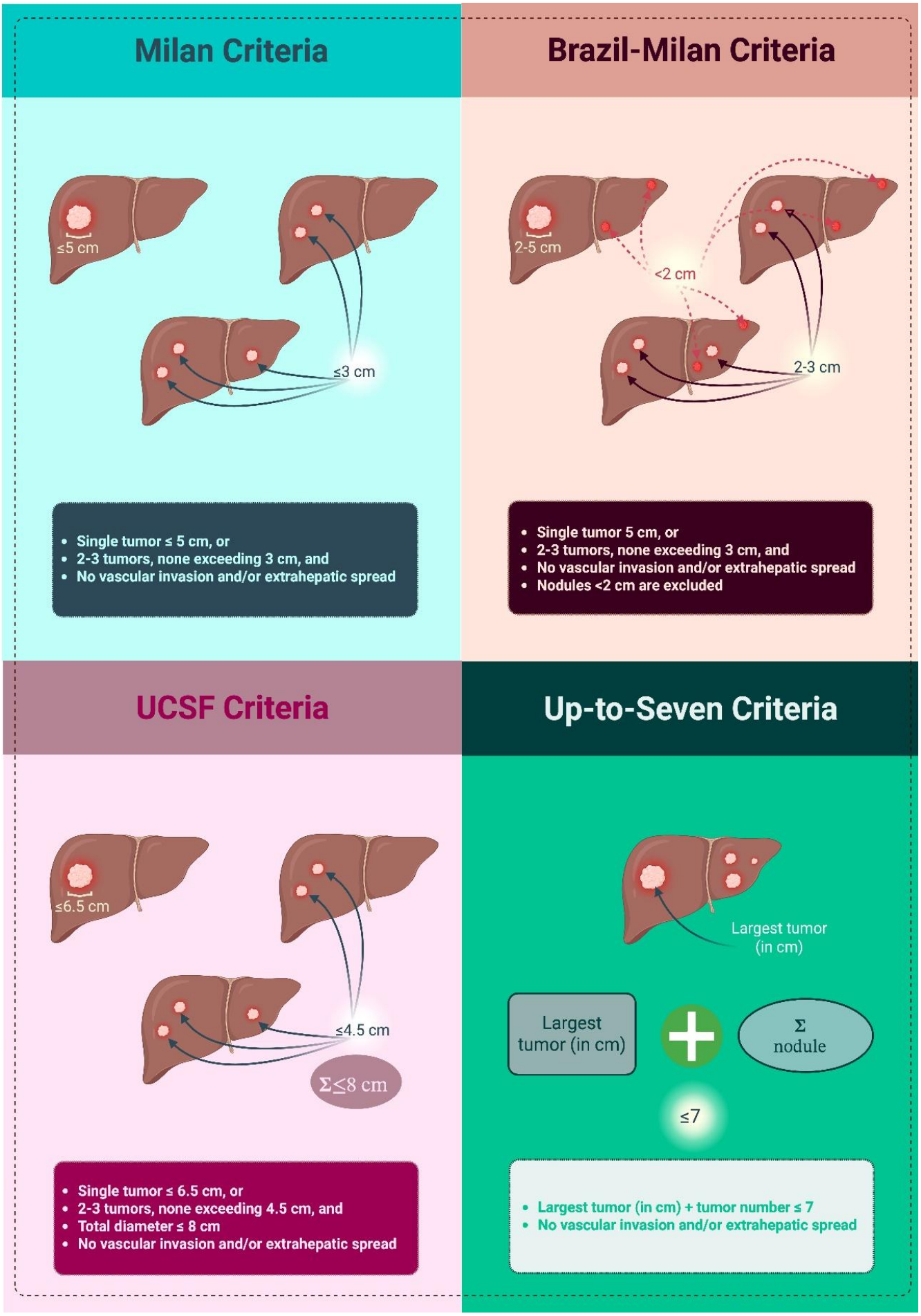

Figure 2. Schematic comparison of the Milan criteria, Brazil-Milan criteria, UCSF (University of California, San Francisco) criteria, and Up-to-Seven criteria, highlighting differences in tumor number, size limits, and eligibility thresholds.

Recommendation 11: A minimally invasive approach is preferred for minor resections in favorable segments, including selected patients with cirrhosis and portal hypertension. Minimally invasive complex procedures, particularly major hepatectomies and resections of the posterosuperior segments, should be performed only by teams with advanced expertise in hepatobiliary and MILS.

Evidence Level: Moderate

Recommendation Grade: Strong

Is there a maximum tumor size that contraindicates hepatic resection in HCC?

Tumor size is an important prognostic factor in HCC, but its role in selecting candidates for hepatic resection has evolved over time. Since the 2011 BCLC update, single HCC without vascular invasion or extrahepatic spread has been classified as early stage (BCLC A), without a strict upper size limit. However, increasing tumor size is associated with more aggressive tumor biology and worse outcomes, which may influence treatment selection[172].

From an oncologic perspective, larger tumors are associated with a higher incidence of microvascular and macrovascular invasion, increased risk of recurrence, and worse long-term outcomes[125,172,216]. These features reflect more aggressive tumor biology and contribute to the heterogeneity of outcomes observed after resection in patients with large HCC.

Clinical data suggest that, although survival decreases with increasing tumor size, hepatic resection may still provide meaningful benefit in selected patients. In a large retrospective analysis of the ITA.LI.CA database including 924 patients, median survival was significantly lower in patients with tumors larger than 5 cm than in those with tumors≤5 cm (44 vs. 78 months; p=0.002). However, resection remained associated with the best survival outcomes in both groups when compared with other treatment modalities. Subgroup analysis identified a tumor size of 7 cm as an independent prognostic threshold, with median survival of 30 months for tumors>7 cm compared with 47 months for tumors≤7 cm[172].

However, tumor size alone does not fully capture tumor behavior or resectability. Other factors, including vascular invasion, tumor differentiation, liver function, and technical feasibility, play a central role in determining outcomes after resection. In addition, treatment strategies may vary according to regional practice patterns and organ allocation policies. In some settings, preoperative locoregional therapy has been used to reduce the viable tumor burden and facilitate subsequent management, including salvage transplantation in cases of recurrence[125,216].

Recommendation 12: Tumor size alone should not contraindicate hepatic resection in HCC, as there is no evidence-based cutoff beyond which surgery is ineffective, and resection may be considered in selected patients based on tumor biology and liver functional reserve.

Evidence Level: Moderate

Recommendation Grade: Weak

Is there a serum alpha-fetoprotein threshold that contraindicates hepatic resection in HCC?

Serum AFP is a well-established HCC biomarker and reflects tumor biology rather than technical resectability. Elevated AFP levels have been consistently associated with more aggressive tumor behavior, including a higher incidence of microvascular invasion, poorer differentiation, and increased risk of recurrence after resection[213].

Several studies have demonstrated a progressive association between increasing AFP levels and worse oncologic outcomes. In a retrospective cohort of 1,182 patients undergoing hepatic resection for HCC, both overall survival and disease-free survival declined with higher preoperative AFP values. Patients with AFP>400 ng/mL had a median disease-free survival of 8.4 months and a median overall survival of 38.4 months, compared with 55.6 months and 133 months, respectively, in patients with AFP <20 ng/mL[30]. These findings illustrate the strong prognostic impact of AFP across a wide range of values.

Despite its prognostic relevance, AFP alone does not define resectability. Its value lies primarily in risk stratification, helping to identify patients with more aggressive tumor biology who may be at higher risk of early recurrence after surgery. AFP should therefore be interpreted in conjunction with other factors, including tumor burden, vascular invasion, and liver function, when evaluating outcomes after hepatic resection in HCC.

Recommendation 13: No serum AFP value contraindicates hepatic resection in HCC, although elevated AFP levels are associated with more aggressive tumor biology and worse prognosis, and should be considered in preoperative risk stratification.

Evidence Level: Moderate

Recommendation Grade: Strong

What is the role of transarterial chemoembolization combined with portal vein embolization in HCC patients with insufficient future liver remnant?

Portal vein embolization (PVE) is an established strategy to increase the safety of major hepatectomy by inducing hypertrophy of the future liver remnant (FLR). By redirecting portal flow to the contralateral liver, PVE promotes compensatory hypertrophy and improves postoperative functional reserve, reducing the risk of post-hepatectomy liver failure in both non-cirrhotic and cirrhotic patients with HCC[11,146,216].

However, PVE is associated with important biological consequences. The diversion of portal flow leads to a compensatory increase in arterial inflow to the embolized liver, which, theoretically, may stimulate tumor growth and progression during the interval before surgery. This phenomenon has been reported to change treatment strategy in a substantial proportion of patients, with disease progression precluding resection in approximately 25% of cases[88,137].

To mitigate this risk, combined approaches integrating locoregional therapies with PVE have been explored. Sequential strategies involving TACE followed by PVE aim to control tumor progression by reducing arterial tumor perfusion while preserving the hypertrophic stimulus induced by portal vein occlusion. This approach may also enhance tumor necrosis and has been associated with greater FLR hypertrophy compared with PVE alone[167,210].

Clinical data support the potential benefits of this combined strategy. In a systematic review and meta-analysis of preoperative strategies to increase the future liver remnant, sequential TACE followed by PVE achieved a higher resection rate than

CC BY

PVE or ligation alone (90 versus 75%) and better overall survival, without an increase in post-hepatectomy liver failure or major complications[216]. These findings suggest that combining arterial and portal interventions may optimize both oncologic control and surgical feasibility in patients with insufficient FLR.

Recommendation 14: In HCC patients with an insufficient future liver remnant, a sequential strategy of TACE followed by PVE should be considered, as it promotes greater liver hypertrophy and leads to better resectability, overall survival, and disease-free survival than PVE alone.

Evidence Level: Moderate

Recommendation Grade: Strong

Anatomic versus non-anatomic resection in HCC: when should each approach be used?

The choice between anatomic resection and non-anatomic resection in HCC reflects the need to balance oncologic radicality with preservation of functional liver parenchyma. On the one hand, surgery should aim to remove the tumor together with its potential portal venous drainage territory. On the other hand, excessive parenchymal sacrifice may increase the risk of postoperative liver failure, particularly in patients with chronic liver disease[26].

The rationale for anatomic resection is based on HCC's biological behavior. Because HCC may invade intrahepatic vascular structures and spread through the portal venous system, resection of the entire portal territory containing the tumor has been considered oncologically advantageous over limited wedge resection[201]. Numerous retrospective studies support this theoretical benefit, reporting lower recurrence rates and improved long-term survival after anatomic resection. However, other studies have not confirmed this advantage, likely reflecting differences in patient selection, tumor burden, liver function, and surgical indication.

In a meta-analysis including 9,444 patients, anatomic resection was associated with better long-term outcomes than non-anatomic resection, although substantial heterogeneity was observed across the surgical series included[130]. Tumor size also appears to influence the magnitude of this benefit. A large population-based study from Japan showed that the oncologic advantage of anatomic resection was more evident in tumors measuring 2 to 5 cm, suggesting that this subgroup may derive the greatest benefit from portal territory-based resection[59].

In clinical practice, liver function and tumor distribution also shape the choice of resection type. In patients with preserved liver function and a technically favorable lesion, anatomic resection may offer better local and intrahepatic disease control. By contrast, non-anatomic resection may be more appropriate when parenchymal preservation is a priority, particularly in patients with limited hepatic reserve, larger tumors requiring broader sacrifice of non-tumoral liver if treated anatomically, or multifocal disease involving different segments[26,130]. These factors explain why the choice between anatomic and non-anatomic resection remains individualized in contemporary surgical management of HCC.

Recommendation 15: Anatomic resection should be preferred in HCC when liver function is preserved, and the procedure is technically feasible, particularly for tumors between 2 and 5 cm; non-anatomic resection should be favored for ≤ 2 cm lesions or when parenchymal preservation is critical, including in patients with borderline liver function, tumors larger than 5 cm, or multifocal disease involving different segments.

Evidence Level: Moderate

Recommendation Grade: Weak

What is the current evidence for neoadjuvant systemic therapy before hepatic resection in HCC?

Neoadjuvant systemic therapy before hepatic resection has not traditionally been part of HCC management. Early interest in this strategy was limited by the modest response rates observed with sorafenib, which reduced its potential value in a preoperative setting. This scenario has changed with the development of immune checkpoint inhibitors, which have shown higher objective response rates in advanced HCC and have renewed interest in perioperative systemic treatment.

Early-phase studies evaluating immunotherapy before surgery have reported encouraging pathological responses. In a small, randomized, phase II trial, perioperative nivolumab, alone or combined with ipilimumab, achieved a major pathological response (≥70% tumor necrosis in the resected specimen) in three of nine and three of eleven resected patients, respectively[97]. Similar findings have been reported in other neoadjuvant studies using combinations of nivolumab, ipilimumab, or cemiplimab, suggesting that immune-based treatment may induce meaningful tumor regression in a subset of patients before resection[5,144].

Despite these promising biological and pathological results, the available evidence remains preliminary. To date, no study has demonstrated a clear survival benefit or established neoadjuvant systemic therapy as part of routine preoperative management before liver resection. Current evidence is derived mainly from small phase I or II studies, with limited sample sizes, heterogeneous treatment regimens, and short follow-up. In addition, the relationship between pathological response and long-term oncologic outcomes after resection remains uncertain.

Several ongoing clinical trials are evaluating immune checkpoint inhibitors, either alone or in combination with other systemic or locoregional therapies, in the neoadjuvant setting, and their results will be important for defining the future role of this strategy in HCC (e.g., NCT03510871, NCT03222076, NCT03299946, NCT03867370, NCT04850040, NCT04615143, NCT04658147)[5]. At present, the evidence supports continued investigation of neoadjuvant systemic therapy, but not its incorporation into standard preoperative practice.

Recommendation 16: At present, there is no evidence to support the routine use of neoadjuvant systemic therapy before hepatic resection in HCC.

Evidence Level: Low

Recommendation Grade: Weak

What is the current evidence for adjuvant therapy after curative treatment of HCC?

Recurrence remains a major limitation after curative-intent treatment for HCC. Even after liver resection or ablation,

CC BY

five-year recurrence rates range from 44% to 79%, reflecting the combined impact of occult micrometastatic disease, microvascular invasion, and the pro-oncogenic background of the cirrhotic liver[135,188,213]. This high recurrence burden supports adjuvant strategies after apparently curative treatment.

To date, however, no adjuvant approach has demonstrated a clear, durable survival benefit to support routine use after resection or ablation. The phase III STORM trial, which included 1,114 patients, showed no improvement in recurrence-free survival with adjuvant sorafenib compared with placebo after curative treatment, and this study established the negative benchmark for adjuvant systemic therapy in HCC[20].

Evidence for adjuvant locoregional therapy has been derived mainly from Eastern series. Meta-analyses suggest possible benefits of adjuvant TACE and hepatic artery infusion chemotherapy, particularly in patients at higher risk of recurrence, but these data come predominantly from Asian populations, and their external validity remains uncertain in other clinical settings[126,236].

More recently, immune checkpoint inhibitors have been investigated in the adjuvant setting. Phase III studies such as CheckMate-9DX and EMERALD-2 were designed to evaluate this strategy after curative-intent treatment, but definitive practice-changing results have not yet been established[66,104]. In a phase II study, adjuvant sintilimab improved recurrence-free survival in patients with microvascular invasion, although overall survival data were not reported[225]. Similarly, adjuvant atezolizumab plus bevacizumab in the phase III IMbrave050 trial initially showed improved recurrence-free survival in high-risk patients, but this benefit was not sustained with longer follow-up, and overall survival data remain immature, with no clear advantage[239]. Interim phase III data with adjuvant pembrolizumab have also not shown improvement in recurrence-free survival after curative-intent resection or ablation.

Taken together, current evidence indicates persistent interest in adjuvant treatment for HCC, especially immunotherapy-based strategies, but the data available remain insufficient to establish a consistent long-term benefit following curative-intent therapy.

Recommendation 17: There is currently insufficient evidence to support the routine use of adjuvant therapy after surgical resection or ablation for HCC.

Evidence Level: High

Recommendation Grade: Weak

What criteria define unresectable HCC and support liver transplantation as the preferred treatment option?

There is no single universal cutoff that defines unresectability in cirrhotic patients with HCC. In practice, the decision depends on the interaction between liver function, portal hypertension, the extent of the planned resection, and tumor distribution. These variables determine whether resection can be performed with an acceptable risk of postoperative liver failure or whether liver transplantation is a more appropriate curative option[65,89,112,134].

Baseline liver function remains a key determinant of surgical candidacy. In general, patients with Child–Pugh A and selected Child–Pugh B7 cirrhosis may be considered for resection, whereas Child–Pugh C is widely regarded as a contraindication to hepatectomy because of the very high risk of postoperative hepatic decompensation[65,89,112,134]. MELD also provides important prognostic information, and values≥10 have been associated with a higher risk of postoperative liver failure and perioperative mortality after liver resection[39,47,65].

Portal hypertension is another key component of this assessment. A hepatic venous pressure gradient below 10 mmHg is used in AASLD and EASL guidance to exclude clinically significant portal hypertension, but many settings, including Brazil, do not routinely measure HVPG. In daily practice, portal hypertension is often inferred from platelet count<100,000/mm³, splenomegaly, varices, and/or ascites. These findings are associated with a higher risk of postoperative liver decompensation, especially when major hepatectomy is required[65,89,217]. In this context, the extent of resection becomes particularly important, as patients with cirrhosis poorly tolerate large-volume liver resections.

Additional functional tools may refine risk stratification. The indocyanine green retention test at 15 minutes has shown greater predictive value than Child–Pugh classification in some series, especially among Child–Pugh A patients, and may help guide the safe extent of hepatectomy, although it is not routinely used in Brazil[92,228].

Tumor distribution also influences whether transplantation becomes preferable to resection. Multifocal tumors involving different hepatic segments may still be technically removable in some cases, but often at the cost of extensive parenchymal sacrifice in an already diseased liver. Likewise, when a cirrhotic patient within Milan criteria would require a major hepatectomy to achieve complete tumor removal, the functional cost of resection may outweigh its potential benefit. In these scenarios, liver transplantation addresses both the tumor and the underlying liver disease and may offer a more appropriate curative strategy.

Recommendation 18: For patients with HCC within the Milan criteria, hepatic resection should generally be avoided in the presence of clinically significant portal hypertension, impaired liver function beyond Child–Pugh A/B7, or evidence of clinically relevant hepatic decompensation. Resection is also not recommended when the procedure would require a major hepatectomy (>2 segments) in cirrhotic patients or when multifocal tumors involve different hepatic segments, situations in which liver transplantation should be considered the preferred curative strategy.

Evidence Level: Moderate

Recommendation Grade: Strong

Hepatic resection or liver transplantation for a single 2–5 cm HCC with preserved liver function: how should treatment be selected?

Liver resection and liver transplantation are both potentially curative options for patients with a single HCC measuring 2–5 cm and preserved liver function[65,76,135,176]. No randomized trials have directly compared these strategies in this population, and available evidence is derived from retrospective series and meta-analyses. When patients are matched for tumor stage, liver transplantation is generally associated with superior disease-free survival due to complete removal of both the tumor and the underlying cirrhotic liver, while overall survival differences are less consistent across studies[135,232].

CC BY

A recent meta-analysis of early-stage disease with a single lesion reported comparable five-year overall survival between liver resection and liver transplantation, with significantly better disease-free survival in the transplant group[105]. These findings reflect the high rate of intrahepatic recurrence after resection, which remains its main limitation. Recurrence rates after liver resection reach 50–70% at five years and are influenced by tumor-related factors such as satellite nodules, multi-nodular disease, elevated AFP levels, microvascular invasion, and poor differentiation[90].

The presence and severity of underlying liver disease play a central role in treatment selection. Data from the Surveillance, Epidemiology, and End Results (SEER) Program within the United Network for Organ Sharing (UNOS) criteria showed that liver transplantation was associated with improved survival in patients with advanced fibrosis or cirrhosis (fibrosis score 5–6), whereas outcomes were similar between liver transplantation and liver resection in patients without fibrosis or with mild-to-moderate fibrosis (fibrosis score 0–4)[232]. These findings highlight that the benefit of liver transplantation is closely linked to the presence of clinically relevant liver disease.

In clinical practice, organ availability also influences treatment choice. Due to limited graft supply and the risk of tumor progression while on the waiting list, most international guidelines favor liver resection as the initial treatment in patients with preserved liver function and no clinically significant portal hypertension[65,89,183]. In Brazil, liver transplantation activity remains below estimated national demand, with approximately 2,400 procedures performed annually compared with a need of around 5,000 transplants per year[17,18]. Allocation policies have also been the subject of ongoing discussion, particularly regarding prioritization of patients with HCC and preserved liver function versus those with high MELD scores without malignancy[9,187].

Given these constraints, liver resection is the first-line strategy for suitable candidates. The concept of salvage transplantation has been incorporated into clinical practice, allowing patients initially treated with resection to be considered for liver transplantation in the event of recurrence, if transplant criteria are still fulfilled. This sequential approach aims to balance immediate treatment with optimal use of limited donor organs while maintaining access to a potentially definitive therapy.

Recommendation 19: In patients with a single HCC measuring 2–5 cm and preserved liver function (Child–Pugh A/B7), hepatic resection should be the preferred first-line treatment when there is no clinically significant portal hypertension. Limited hepatic resection (up to two segments) may be considered in selected cirrhotic patients with mild portal hypertension and preserved liver function. In the presence of clinically significant portal hypertension, liver transplantation should be considered the preferred curative strategy. For patients initially treated with resection, liver transplantation may be considered as a salvage option in cases of tumor recurrence, provided transplant criteria are still met.

Evidence Level: High

Recommendation Grade: Strong

What are the indications for liver transplantation in patients with HCC in Brazil?

Liver transplantation is an established curative treatment for early-stage HCC, offering the advantage of removing both the tumor and the underlying cirrhotic liver. This dual effect is associated with excellent oncologic outcomes, with 5-year overall survival rates exceeding 70% and relatively low recurrence rates, typically ranging from 8 to 20% in appropriately selected patients[65,147,149,176,183].

Patient selection for liver transplantation is primarily based on tumor burden. The Milan criteria remain the standard benchmark, defined as a single lesion ≤5 cm or up to three lesions each ≤3 cm, without vascular invasion or extrahepatic disease. Patients meeting these criteria consistently achieve favorable long-term outcomes, supporting their widespread adoption in allocation policies and clinical practice[147,152,153,176].

Tumor biology also plays a critical role in predicting outcomes after liver transplantation. AFP has been consistently associated with tumor aggressiveness, including microvascular invasion and poor differentiation[78,152,164,219]. Higher AFP levels are associated with an increased risk of post-transplant recurrence. Although no universal cutoff has been established, values above 100 ng/mL have been associated with worse outcomes, and levels exceeding 1,000 ng/mL are frequently considered indicative of high recurrence risk[147,148,149,150,151]. In the United States, current allocation policies require patients with AFP>1000 ng/mL to reduce it to <500 ng/mL after locoregional therapy before being listed for transplantation, a strategy associated with improved post-transplant survival and disease-free survival[84,153,154].

Brazilian data reinforce AFP's prognostic value. In a multicenter cohort of 1,119 patients undergoing liver transplantation for HCC, those with pre-transplant AFP≤200 ng/mL had significantly better 5-year overall survival than those with AFP>200 ng/mL (76 vs. 66%; p<0.001). Elevated AFP (>200 ng/mL) and being outside Milan criteria at diagnosis were independently associated with recurrence and worse post-transplant outcomes[28].

In Brazil, the liver transplantation policy for HCC must also be interpreted in light of organ shortages and national allocation rules. To encourage resection in potentially resectable cases, the Brazilian Ministry of Health issued Ordinance No. 656, of April 1, 2020, based on the opinion of the National Technical Chamber. Under this policy, patients with HCC≥2 cm within the Milan criteria who undergo hepatic resection may receive priority access to liver transplantation through the MELD exception in two situations. The first is recurrence within two years after resection, provided it remains within Milan criteria on imaging; in that case, the MELD score may be granted retroactively to the date of resection. The second is severe postoperative liver failure after resection, in which case MELD 40 may be granted if reported up to postoperative day 15, and MELD 30 thereafter, with this special status remaining valid for up to 60 days and subject to review by the National Technical Chamber[19].

This regulatory framework is particularly relevant in Brazil because it links the initial use of hepatic resection to the possibility of subsequent salvage liver transplantation in selected patients, while also recognizing postoperative liver failure after liver resection as a situation warranting transplant priority. For this reason, indications for liver transplantation in Brazilian patients with HCC are guided not only by tumor burden and liver function but also by the interplay among resection strategies, recurrence patterns, and the national allocation policy.

Recommendation 20: In Brazil, liver transplantation is recommended as a first-line treatment option for patients with HCC

CC BY

≥2 cm associated with cirrhosis, within Milan criteria, with AFP ≤1000 ng/mL, including after locoregional therapy, who are not candidates for resection, and who have no contraindication to transplantation. In addition, for patients with HCC ≥2 cm within Milan criteria who undergo resection, liver transplantation may be prioritized in cases of recurrence within two years, if Milan criteria are still met, with MELD retroactive to the date of resection, or in cases of severe postoperative liver failure, with MELD 40 if reported by postoperative day 15 and MELD 30 thereafter, valid for up to 60 days and subject to review by the National Technical Chamber.

Evidence Level: Moderate

Recommendation Grade: Weak

What is the role of expanded transplant criteria beyond the Milan criteria for HCC in Brazil?

The Milan criteria remain the most widely adopted selection standard for liver transplantation in HCC and are a benchmark for comparison with expanded criteria in most Western guidelines[65,89,134]. However, their restrictive nature has led to the development of alternative models aiming to identify patients outside Milan who may still achieve acceptable post-transplant outcomes.

Among these, the UCSF (University of California, San Francisco) criteria and the Up-to-Seven criteria are the most extensively studied (Figure 2). These models expand morphological limits while maintaining acceptable survival, with several studies reporting post-liver transplantation outcomes comparable to those observed within Milan in selected populations[95,120,151,171,189,235]. Nonetheless, progressive expansion of tumor burden is associated with a decline in post-transplant survival, as illustrated by the "metro ticket" concept, in which increasing tumor extent correlates with worse outcomes[151].

In addition to morphological criteria, there has been growing interest in incorporating markers of tumor biology into selection algorithms. AFP is the most consistently validated biomarker, with higher levels associated with microvascular invasion, poor differentiation, and increased risk of recurrence after liver transplantation. Multiple AFP thresholds have been proposed, including 100, 200, 400, and 1,000 ng/mL, but there is no consensus on how best to integrate AFP with morphological criteria[32,78,84,153]. Other markers, such as tumor differentiation on biopsy, microvascular invasion, FDG-PET uptake, PIVKA-II, and circulating microRNAs, have been explored in selected centers but remain investigational and lack widespread validation[182,196].

Response to locoregional therapy has also emerged as a relevant dynamic marker of tumor behavior. Patients initially beyond Milan criteria may be considered for liver transplantation after successful downstaging to within Milan limits, an approach supported by major Western guidelines, including AASLD, EASL, and recent BCLC updates[65,89,134,183]. However, expansion of liver transplantation eligibility must be balanced against organ scarcity, as broader criteria may impact waiting list dynamics and access for patients without HCC[190].

In Brazil, liver transplantation eligibility for HCC is formally restricted to patients who meet Milan criteria and have AFP<1,000 ng/mL under the current national allocation policy[17]. A local adaptation, known as the "Brazil-Milan criteria," reflects historical diagnostic limitations at the time of MELD implementation, whereby nodules smaller than 2 cm are not considered for listing. This approach may exclude patients with small tumors who could benefit from curative local therapies while allowing inclusion of patients with multifocal disease that would otherwise exceed conventional Milan limits[28,29].

National data have provided insight into outcomes under this model. In a multicenter Brazilian cohort of more than 1,000 patients, those outside conventional Milan criteria but within Brazil-Milan criteria had worse overall and disease-free survival compared with patients strictly within Milan limits[162]. In another national series of 1,059 transplanted patients, overall five-year survival reached approximately 63%, with recurrence rates around 8%. Outcomes were significantly better in patients meeting Milan criteria at both diagnosis and explant[28]. A regional study from São Paulo, including 414 cases, showed that approximately 8.6% of patients were outside Milan but within Brazil-Milan criteria, with similar five-year survival between groups[190].

Taken together, these findings suggest that while expanded criteria may allow broader access to liver transplantation, outcomes remain more favorable in patients within conventional Milan criteria. In Brazil, current policy reflects a pragmatic balance between expanding access and preserving acceptable post-transplant outcomes, although international validation of the Brazil-Milan model is lacking.

Recommendation 21: The Milan criteria should remain the reference standard for liver transplantation for HCC in Brazil. Patients who do not meet these criteria may be considered for transplantation only after successful downstaging to within the Milan criteria, in the absence of macrovascular invasion or extrahepatic disease.

Evidence Level: Moderate

Recommendation Grade: Weak

For which patients and in which scenarios should living-donor liver transplantation be considered for HCC?

Living-donor liver transplantation (LDLT) and deceased-donor liver transplantation (DDLT) have been extensively compared in patients with HCC. A meta-analysis of 29 studies and 5,376 patients demonstrated that LDLT achieves perioperative and long-term survival outcomes comparable to those of DDLT[246]. However, from a broader societal perspective, LDLT offers important advantages, including shorter waiting times, lower dropout rates, and improved long-term survival, reflecting a reduced risk of tumor progression while awaiting transplantation[116,129].

Because LDLT is not constrained by deceased-donor allocation systems, it offers greater flexibility in patient selection. This has allowed some centers to explore transplantation beyond the Milan criteria, particularly in patients with favorable tumor biology. Selection in this context requires careful, individualized assessment that integrates factors such as tumor growth dynamics, AFP levels, histological features, the presence of microvascular invasion, response to locoregional therapy, patient-related factors, and expected oncologic outcomes[139,152].

Several expanded criteria, including UCSF, Up-to-Seven, and Toronto criteria, have been applied in LDLT with reported five-year survival rates exceeding those achieved with non-

transplant therapies in selected patients[83,120,121,196]. Nevertheless, the acceptable threshold of post-transplant survival remains a critical consideration given the involvement of a healthy donor. Although there is no universal consensus, survival rates above 50% at five years have been proposed as a minimum benchmark, with more recent recommendations suggesting that outcomes should exceed 60% to justify donor risk[153].

The International Liver Transplantation Society (ILTS) consensus emphasizes the importance of tumor biology in selecting candidates for LDLT beyond the Milan criteria. Parameters such as AFP<400 ng/mL, absence of FDG uptake on positron emission tomography (PET) imaging, and favorable response to locoregional therapy have been associated with improved post-transplant outcomes, whereas the presence of macrovascular invasion or extrahepatic disease is associated with poor prognosis and should be excluded[153].

Donor safety remains the main limiting factor for LDLT. Large international series have reported donor mortality rates around 0.2%, with overall morbidity ranging from 24 to 38% and severe complications occurring in approximately 1% of cases[1,2]. These risks require careful donor selection and strict adherence to safety protocols. For this reason, LDLT should be performed in high-volume centers with extensive experience in both transplantation and hepatobiliary surgery[2,139].

Technical factors also influence feasibility and outcomes. In some recipients, anatomical considerations, graft size mismatch, or prior abdominal surgery may limit LDLT applicability. In addition, biliary complications are more frequent after LDLT compared with DDLT and may require postoperative intervention[2,153].

In Brazil, adult LDLT remains infrequent. Data from the Registro Brasileiro de Transplantes indicate that, among 6,297 liver transplants performed in 2024, only 912 (14.5%) were LDLT procedures, highlighting the limited adoption of this approach nationwide[70].

Recommendation 22: LDLT may be considered for selected patients with HCC, particularly when deceased-donor access is limited, provided there is favorable tumor biology and no macrovascular invasion or extrahepatic disease.

Evidence Level: Moderate

Recommendation Grade: Weak

When should bridge therapy be used, and which modality should be selected in HCC patients listed for liver transplantation?

In regions with limited organ availability, prolonged waiting times for liver transplantation increase the risk of tumor progression, waitlist dropout, and death in patients with HCC. In this context, bridge therapy (BT) has been used to maintain patients within transplant criteria and reduce the risk of disease progression during the waiting period. Current evidence supports its use, particularly when the expected waiting time exceeds six months[40,234].

Beyond tumor control, response to locoregional therapy has emerged as an important marker of tumor biology. Several studies have shown that patients who achieve a favorable response to locoregional therapy before transplantation have improved post-transplant outcomes, including lower recurrence rates and better overall survival[4,55,60,159]. In a systematic review of 15 studies, patients with radiological or pathological response to locoregional therapy had improved survival and lower recurrence rates, although the available evidence was derived from observational studies[159].

The pathological response appears particularly relevant. A large European multicenter study demonstrated that the presence of a viable tumor≥2 cm in the treated lesion was strongly associated with post-transplant recurrence[142]. Similarly, data from a large American multicenter cohort showed that complete pathological response after locoregional therapy was associated with lower recurrence rates and improved survival after transplantation[55]. These findings support the role of locoregional therapy not only as a bridging strategy but also as a tool to assess tumor behavior and refine candidate selection.

More recent data suggest that locoregional therapy may also be used with a neoadjuvant intent, aiming to maximize tumor necrosis before transplantation and further select patients with favorable tumor biology[45,142]. This dynamic assessment complements static criteria such as tumor size and number and has been incorporated into selection strategies in several centers[152,153].

Multiple locoregional therapy modalities are available for use as bridge therapy. TACE is the most used approach, followed by thermal ablation techniques such as RFA and MWA. MWA has been increasingly used in selected cases, particularly for larger lesions or tumors adjacent to vessels. Stereotactic body radiotherapy (SBRT) has also been used when other locoregional therapies are not feasible. Comparative studies have not demonstrated clear superiority of one modality over another, and treatment selection is generally based on tumor characteristics, technical feasibility, and institutional expertise[65,140,184].

Data from Brazil reflect the real-world application of these strategies. In a multicenter study, the mean waiting time for transplantation was 9.8 months, but approximately half of patients waited for more than six months. Bridge therapy was used in 68% of patients, most commonly TACE (80%), followed by PEI (9%), RFA (3%), surgery (1%), and combined approaches (7%). According to mRECIST criteria, 37% of patients achieved complete response and 38% partial response. Overall five-year survival was 63%, with post-transplant recurrence of 8%, and no significant difference in overall survival between patients who received BT and those who did not. However, a complete response to locoregional therapy was associated with improved recurrence-free survival[28].

Recommendation 23: In HCC patients listed for liver transplantation within the Milan criteria, bridge therapy should be considered to reduce the risk of tumor progression and waitlist dropout, and no specific locoregional modality should be preferred over another, with the choice guided by tumor characteristics, technical feasibility, and local expertise.

Evidence Level: Moderate

Recommendation Grade: Weak

Is there an upper age limit that contraindicates liver transplantation in HCC?

Older candidates frequently present with a higher burden of comorbidities and reduced physiological reserve, which are associated with increased waitlist mortality and higher post-transplant mortality compared with younger recipients[43]. For this reason, age has been consistently associated with worse

CC BY

long-term outcomes. Although one-year survival may be similar between younger and older recipients, several studies report significantly lower five-year survival in patients aged≥60–70 years[43,56,57]. A meta-analysis including recipients aged≥70 years reported one- and five-year survival rates of 78.7 and 48.9%, respectively, compared with 86.6 and 70.1% in younger patients, and higher perioperative mortality[157]. Cardiovascular complications are a major contributor to early mortality after liver transplantation. They are more frequent in older recipients, particularly in those with metabolic comorbidities such as metabolic dysfunction-associated steatohepatitis, diabetes, and hypertension, as well as pulmonary disease[110].

Even so, over recent decades, the age of transplant recipients has progressively increased across different regions, including the United States, Europe, and Brazil[56,69,77]. Registry data from UNOS, the Organ Procurement and Transplantation Network (OPTN), and the European Liver Transplant Registry demonstrate a growing proportion of recipients aged≥65 and ≥70 years. In the United States, the proportion of recipients aged 65 years or older increased from 8% in 2002 to 23% in 2019[115]. The increasing incidence of HCC and metabolic dysfunction-associated steatohepatitis in older populations largely drives this trend[57].

Current international guidelines do not define a strict age cutoff for liver transplantation. Both AASLD and EASL recommend basing candidacy on physiological rather than chronological age, emphasizing the importance of evaluating comorbidities, functional status, and frailty[63,145]. This approach reflects the heterogeneity among older patients, in whom chronological age alone does not adequately capture operative risk.

In Brazil, national regulations allow listing of patients aged≥70 years for transplantation. However, in clinical practice, many centers adopt a cautious approach, reflecting concerns regarding postoperative outcomes and the potential impact of organ allocation in the setting of limited donor availability.

Recommendation 24: Advanced age alone should not contraindicate liver transplantation in HCC, and candidate selection should be based on physiological status, comorbidities, and functional reserve rather than age.

Evidence Level: Low

Recommendation Grade: Strong

Does a history of extrahepatic malignancy contraindicate liver transplantation in HCC, and how should eligibility be assessed?

A prior history of extrahepatic malignancy introduces an additional risk of tumor recurrence in the setting of post-transplant immunosuppression and may adversely affect long-term survival[6,49].

All candidates with a history of malignancy require careful oncologic evaluation. This assessment should include tumor histology, stage at diagnosis, treatments received, response to therapy, duration of remission, and surveillance history. These factors allow estimation of recurrence risk and cancer-specific survival, which must be interpreted in the context of the expected outcomes after transplantation[16,191]. The objective of this evaluation is to ensure that transplantation is not compromised by recurrence of the prior malignancy and that overall post-transplant survival remains acceptable[86].

In this setting, expected survival after transplantation reflects the interaction between transplant-related outcomes and the natural history of the prior malignancy. Given the scarcity of donor organs, acceptable benefit thresholds are essential. A minimum overall survival of approximately 50% at five years is generally considered necessary to justify transplantation, whereas standard liver transplantation candidates typically achieve five-year survival rates around 70–75%[135]. For patients with a history of malignancy, this implies that the estimated cancer-specific survival should be sufficiently high—typically in the range of 75–80% at five years—to maintain an acceptable overall survival probability after liver transplantation[6,42,86,153].

A disease-free interval after completing cancer treatment is commonly required before listing, as it allows confirmation of sustained remission and provides indirect evidence of tumor biology. The duration of this interval varies according to tumor type and stage, although exceptions may be made for selected early-stage or in situ malignancies[6,42]. Because robust evidence specific to liver transplantation is limited, many recommendations are extrapolated from other solid organ transplant settings[6,61,86].

Recommendation 25: A history of treated extrahepatic malignancy does not in itself contraindicate liver transplantation in HCC, but listing should be considered only after completion of cancer therapy, an adequate disease-free interval, and multidisciplinary assessment of recurrence risk and expected post-transplant survival.

Evidence Level: Low

Recommendation Grade: Weak

Is there evidence to support a personalized immunosuppression strategy using mTOR inhibitors after liver transplantation for HCC?

Immunosuppressive strategy after liver transplantation has been associated with oncologic outcomes in patients with HCC. Some studies have reported that higher exposure to calcineurin inhibitors (CNIs), such as tacrolimus and cyclosporine, is associated with an increased risk of post-transplant tumor recurrence, suggesting a dose-dependent effect on tumor progression under immunosuppression[186,223,224].

mTOR inhibitors, including sirolimus and everolimus, have been proposed as an alternative immunosuppressive strategy because of their antiproliferative and anti-angiogenic properties. Although these agents have demonstrated antitumor activity in other malignancies, their role in HCC remains less clearly defined, and no direct therapeutic effect has been established in this setting[87,100].

Recent observational studies have suggested a potential oncologic benefit associated with mTOR-based regimens after liver transplantation. In a propensity-weighted retrospective analysis of 511 recipients with HCC, everolimus-based immunosuppression was associated with a lower rate of post-transplant recurrence compared with tacrolimus-based regimens (7.7 vs. 16.9%; relative risk (RR)=0.45), with greater apparent benefit in patients with more advanced tumors and in those exposed earlier and for longer durations to everolimus[54]. Similarly, a multicenter retrospective study suggested that sirolimus-based regimens may be associated with improved outcomes in patients exceeding conventional transplant criteria, including reduced non-tumor-related mortality in higher-

risk populations[242]. However, these findings are derived from non-randomized data and are subject to selection bias.

Prospective evidence remains limited. The SiLVER trial, the only randomized study addressing this question, did not demonstrate sustained improvement in recurrence-free survival with sirolimus-based immunosuppression. However, exploratory analyses suggested a possible short-term benefit in selected subgroups[75].

More recent expert recommendations have moved toward individualized immunosuppression strategies. The 2024 update from the Italian Liver Transplant Working Group suggests minimizing CNI exposure and incorporating everolimus in patients transplanted for oncologic indications, particularly those at higher risk of recurrence or with competing risks such as renal dysfunction[141].

Recommendation 26: High exposure to CNIs should be avoided after liver transplantation for HCC, and mTOR-based immunosuppression may be considered as a strategy to potentially reduce the risk of tumor recurrence.

Evidence Level: Low

Recommendation Grade: Weak

What is the therapeutic approach for intrahepatic recurrence after liver transplantation for HCC?

Recurrence of HCC after liver transplantation occurs in approximately 8–20% of recipients, even under restrictive selection criteria, and is associated with poor prognosis, with a median post-recurrence survival of around 12–13 months[7,195]. Most recurrences develop within the first two years after transplantation, reflecting aggressive tumor biology and occult disease at the time of liver transplantation. The predominant pattern is extrahepatic relapse, most commonly involving the lungs and bones, whereas intrahepatic recurrence accounts for approximately 27–45% of cases[51,80,195,233].

Data from a large, multicenter Latin American cohort including 1,085 transplanted patients reported a recurrence rate of 16.6% and a median time to recurrence of 13 months. Early recurrence, defined as occurring within the first year after liver transplantation, was independently associated with worse survival, highlighting its role as a surrogate marker of aggressive tumor behavior[138].

Management of post-transplant recurrence remains heterogeneous, and no standardized treatment algorithm has been established. Available evidence comes mainly from retrospective series, and therapeutic strategies vary by disease distribution, tumor burden, and patient condition[169]. In patients with isolated intrahepatic recurrence, locoregional approaches such as surgical resection, RFA, MWA, radiotherapy, or TACE have been used. In contrast, systemic therapy is generally reserved for patients with unresectable or disseminated disease[169].

Treatment selection depends heavily on the extent of recurrence. A significant proportion of patients present with multifocal or extrahepatic disease, which limits the role of surgical intervention. In contrast, patients with isolated intrahepatic recurrence may be candidates for potentially curative approaches. A recent systematic review and meta-analysis demonstrated that, among patients with single-nodule recurrence, surgical resection was associated with improved one-year overall survival compared with locoregional therapies (71 vs. 62%; p=0.038), supporting the role of surgery in carefully selected cases[169].

Recommendation 27: In patients with intrahepatic recurrence of HCC after liver transplantation, surgical resection or other locoregional therapies should be considered whenever feasible, and systemic therapy should be used when locoregional treatments are not possible.

Evidence Level: Low

Recommendation Grade: Strong

What is the standard locoregional therapy for intermediate-stage (BCLC B) HCC?

TACE is the standard treatment for patients with intermediate-stage (BCLC B) HCC, defined as multinodular disease without vascular invasion or extrahepatic spread, with preserved liver function and good performance status[33,64,89,183,245]. In appropriately selected patients, TACE is associated with a median survival exceeding 2.5 years and remains the reference locoregional therapy in this stage.

TACE's therapeutic effect relies on a dual mechanism: selective arterial embolization and local delivery of cytotoxic agents. HCC is typically hypervascular and predominantly supplied by the hepatic artery, allowing targeted embolization to induce ischemia and tumor necrosis while maintaining high local concentrations of chemotherapy. Common agents include doxorubicin, epirubicin, or cisplatin, often combined with lipiodol or other carriers. TACE can be performed as conventional TACE (cTACE) or using drug-eluting beads (DEB-TACE), which release chemotherapy in a controlled manner[181].

DEB-TACE has been associated with reduced systemic exposure to chemotherapy and, in some studies, improved radiological response rates compared with cTACE. However, most meta-analyses and systematic reviews have not demonstrated a significant difference in overall survival between the two techniques, indicating comparable long-term outcomes[12,22,23,117].

Outcomes after TACE are strongly influenced by patient selection and technical factors. In selected patients with preserved liver function and superselective embolization, median survival may reach 40–50 months[22,208]. However, BCLC B represents a highly heterogeneous population, with variability in tumor burden, liver function, and tumor biology, including AFP levels, all of which influence prognosis and treatment response[134,183]. More recent BCLC updates recognize this heterogeneity and propose subclassification within BCLC B, suggesting that patients with diffuse, infiltrative, or extensive bilobar disease may benefit more from systemic therapy than TACE[183].

TACE is generally indicated in patients with Child–Pugh A to B7 liver function and an ECOG performance status of 0[202]. The presence of clinically significant portal hypertension, portal vein thrombosis, or hyperbilirubinemia (bilirubin>2 mg/dL) increases the risk of post-procedural liver failure and should be carefully considered. TACE is contraindicated in patients with Child–Pugh C cirrhosis[202].

Despite these recommendations, TACE is frequently applied beyond its classical indication in real-world practice, including in patients with early-stage disease or even vascular invasion, reflecting its widespread availability and technical

CC BY

versatility[181]. Overall, consistent evidence supports its role as standard therapy in BCLC B, although its optimal use requires careful stratification of patients within this heterogeneous stage.

Recommendation 28: TACE is the standard treatment for intermediate-stage HCC (BCLC B) in patients with non-diffuse intrahepatic disease and suitable arterial anatomy. DEB-TACE may be preferred to reduce systemic toxicity, with survival comparable to that of conventional TACE.

Evidence Level: High

Recommendation Grade: Strong

What are the recommendations for transarterial radioembolization in intermediate- and advanced-stage HCC?

TARE has emerged as an effective locoregional treatment for unresectable HCC and may be used in both intermediate- and selected advanced-stage disease. In addition to tumor control, TARE has been applied in downstaging strategies before liver transplantation and in the concept of radiation lobectomy, in which targeted irradiation induces hypertrophy of the contralateral liver, potentially enabling subsequent surgical resection[136,177].

TARE consists of intra-arterial delivery of Yttrium-90–loaded microspheres, allowing selective internal radiation with high tumoricidal doses. Unlike TACE, TARE has minimal embolic effect, preserving arterial flow and allowing use in patients with PVT, including tumor-related invasion, where TACE is often contraindicated or associated with higher risk[93,106,114].

Several studies have evaluated the comparative efficacy of TARE and TACE. A meta-analysis including 284 patients treated with TACE and 269 with TARE did not demonstrate a significant difference in overall survival between the two modalities. However, TARE was associated with less post-procedural pain and greater fatigue[136]. In contrast, a randomized phase II trial in patients with BCLC A–B disease showed a significantly longer time to progression with TARE (>26 months) compared with cTACE (6.8 months; p=0.0012), suggesting a potential advantage in delaying tumor progression and reducing dropout in transplant candidates[192].

In advanced-stage disease, two randomized trials (SARAH and SIRveNIB) comparing TARE with sorafenib in patients with locally advanced HCC did not demonstrate a survival benefit with TARE. However, treatment-related toxicity was lower with TARE, with fewer grade≥3 adverse events compared with sorafenib[36,221]. More recently, the DOSISPHERE-01 trial demonstrated that personalized dosimetry with higher radiation doses to the tumor significantly improved objective response compared with standard dosimetry, supporting a dose–response relationship and highlighting the importance of treatment optimization[74].

Highly selective approaches, such as radiation segmentectomy and radiation lobectomy, have expanded the role of TARE. Retrospective series have shown durable local control with radiation segmentectomy, with outcomes approaching those of thermal ablation in selected patients who are not candidates for percutaneous techniques. Radiation lobectomy may also induce hypertrophy of the future liver remnant, facilitating resection in borderline cases.

TARE has been incorporated into recent treatment algorithms. The BCLC 2022 update recognizes TARE as an ablative option in selected patients, supported by prospective data such as the LEGACY study, which reported a 36-month overall survival of 86.6% in patients with small tumors, and the RASER trial, which demonstrated one- and two-year survival rates of 96% in a similar population[183,193].

Patient selection remains critical. TARE is generally indicated in patients with preserved liver function and limited tumor burden. Elevated bilirubin levels, particularly above 2 mg/dL, are associated with increased risk of radiation-induced liver disease and biliary toxicity and should be carefully considered when selecting candidates[177]. Overall, TARE provides a versatile locoregional option across different clinical scenarios, particularly when TACE is not feasible or when vascular invasion is present.

Recommendation 29: TARE is an alternative intra-arterial therapy to TACE in patients with BCLC B HCC with non-diffuse disease and may be considered in patients with portal vein tumor thrombosis (BCLC C), particularly when thrombosis involves lobar or segmental branches, provided liver function is preserved, and there is no clinically significant hyperbilirubinemia.

Evidence Level: High

Recommendation Grade: Weak

When should radiofrequency ablation be used for HCC?

RFA is a well-established curative-intent treatment for early-stage HCC (BCLC 0–A), particularly in patients with preserved liver function. Its minimally invasive nature, low morbidity, and shorter hospital stay have supported its widespread use, especially in patients who are not optimal candidates for surgical resection or liver transplantation[67,183].

In very early-stage HCC (solitary tumors≤2 cm), RFA achieves overall survival comparable to surgical resection, with lower procedural morbidity and faster recovery[34,35,67,174]. In this setting, outcomes are driven primarily by tumor biology rather than treatment modality. For tumors larger than 2 cm, however, surgical resection has been associated with lower recurrence rates, reflecting a higher likelihood of complete tumor clearance and treatment of potential microscopic spread[123].

RFA is also an accepted option for patients with limited multi-nodular disease (up to three nodules≤3 cm), particularly when transplantation is not feasible. Major guidelines, including BCLC and the Japan Society of Hepatology (JSH), support this indication and reflect the balance between tumor control and preservation of liver function in patients with cirrhosis[107,112,183].

Tumor size is a key determinant of treatment efficacy. The best outcomes are observed in lesions smaller than 3 cm: in a randomized trial restricted to tumors≤3 cm, 5-year overall survival reached 70.4% after ablation and 74.6% after resection, with no significant difference between groups[98]. In contrast, local control declines in tumors larger than 3 cm, where complete ablation becomes less reliable. Histopathological studies have shown that larger tumor size and proximity to vascular structures are associated with higher rates of incomplete necrosis and local recurrence[123].

Tumor location is equally important in treatment planning. Lesions adjacent to central bile ducts are associated with a higher risk of biliary injury and are generally not suitable for RFA. Tumors near the diaphragm, gallbladder, or other adjacent organs may require protective techniques, such as hydrodissection, to reduce procedural risk[123]. In addition, heat-

sink effects from adjacent large vessels may limit thermal ablation effectiveness by reducing the extent of tumor necrosis[123].

The choice between RFA and surgical resection should be individualized, considering tumor size, location, underlying liver function, and the need to preserve functional parenchyma. RFA is particularly advantageous for deeply located lesions in which resection would require disproportionate loss of liver tissue, whereas subcapsular or exophytic tumors may be more amenable to surgical approaches. In resource-constrained settings, RFA is also a cost-effective alternative for treating small HCC[47,65,71,174].

Recommendation 30: RFA should be used for early-stage HCC patients with preserved liver function who are not ideal candidates for surgical resection or liver transplantation, particularly for tumors up to 3 cm located away from major vessels, bile ducts, and adjacent organs, with the best outcomes observed in lesions ≤2 cm.

Evidence Level: High
Recommendation Grade: Strong

When should combined transarterial chemoembolization and radiofrequency ablation be used in the management of HCC?

The combination of TACE and RFA has been explored to enhance local tumor control through complementary mechanisms. TACE reduces arterial inflow, which may decrease the heat-sink effect and increase the extent of thermal injury during ablation. It may also expand the effective treatment area and improve the coverage of satellite nodules, thereby reducing the risk of incomplete ablation[24].

For tumors≤3 cm, most studies have not demonstrated a clear benefit of adding TACE to RFA compared with RFA alone, suggesting that thermal ablation is sufficient to achieve adequate local control in small lesions[103]. In selected scenarios, such as subdiaphragmatic tumors or lesions adjacent to large vessels, the combination may improve technical efficacy by mitigating heat-sink effects[103].

In contrast, for tumors between 3 and 5 cm, the combination of TACE followed by RFA has been associated with improved outcomes compared with RFA alone. Randomized data have shown superior overall survival and recurrence-free survival with the combined approach in this subgroup, with outcomes approaching those observed after surgical resection in selected patients[103,174,175]. In a prospective randomized study including patients with tumors≤5 cm, sequential TACE and RFA improved overall and recurrence-free survival in tumors measuring 3.1–5 cm, whereas no benefit was observed for tumors≤3 cm[174,175].

These findings support a size-dependent effect of combination therapy, in which adding TACE may compensate for the limitations of thermal ablation in larger tumors. Overall, the role of combined TACE and RFA is most relevant for intermediate-sized lesions, particularly when surgical options are not feasible, and should be considered within the context of individualized treatment planning.

Recommendation 31: In patients with HCC being managed with locoregional therapy, particularly those with tumors between 3 and 5 cm who are not candidates for surgical resection or transplantation, the combination of TACE followed by RFA may be considered.

Evidence Level: Moderate
Recommendation Grade: Weak

When should percutaneous ethanol injection be used for HCC?

PEI is an established locoregional therapy for small HCC and has historically played an important role in the management of early-stage disease. In tumors≤2 cm, PEI can achieve complete tumor necrosis in a high proportion of patients, with rates approaching 90% in selected series, supporting its use as a potentially curative option in carefully selected cases[58,133].

Its efficacy, however, is strongly dependent on tumor size. In lesions>2 cm, ethanol distribution becomes less homogeneous, leading to higher rates of incomplete necrosis and local recurrence[131,132]. Although PEI is safe, well-tolerated, and relatively inexpensive, it typically requires multiple treatment sessions and has consistently shown inferior local control compared with thermal ablation techniques[163].

Over time, RFA has largely replaced PEI as the preferred ablative modality. Randomized trials have demonstrated superior local tumor control and improved long-term outcomes with RFA, including higher overall survival rates compared with PEI[163,198]. As a result, the use of PEI has become more selective in contemporary practice.

Despite these limitations, PEI retains a role in specific clinical scenarios. It may be considered in small tumors when thermal ablation is contraindicated, particularly in lesions adjacent to central bile ducts or hollow viscera, where the risk of thermal injury is significant. In addition, PEI remains relevant in settings with limited access to RFA or MWA, offering a low-cost, widely available alternative[34,163,198].

Recommendation 32: PEI may be used for HCC up to 2 cm when surgical resection or thermal ablation are not feasible or not available, particularly in tumors located close to bile ducts or hollow viscera.

Evidence Level: High
Recommendation Grade: Strong

What is the role of microwave ablation in the treatment of HCC?

MWA is a thermal ablative technique developed after RFA and has theoretical technical advantages, including the ability to generate higher intratumoral temperatures, produce larger and more homogeneous ablation zones, and achieve shorter ablation times. In addition, MWA is less susceptible to the heat-sink effect caused by adjacent blood flow, which may improve efficacy in tumors located near large vessels[230].

Despite these technical differences, comparative clinical evidence has not demonstrated a consistent superiority of MWA over RFA in long-term oncologic outcomes. Multiple randomized trials have shown similar results between the two techniques in terms of safety, complication rates, local tumor control, and overall survival[200,220,240]. Procedural differences have been observed, with some studies reporting fewer needle insertions and shorter ablation times with MWA[240].

A systematic review and meta-analysis including 26 studies (five randomized trials and 21 cohort studies) and 4,396 patients found no significant differences in long-term outcomes

CC BY

between the two techniques. Overall survival (hazard ratio (HR)=0.891; p=0.222) and disease-free survival (HR=1.014; p=0.852) were comparable between MWA and RFA. Tumor progression rates were also similar (17.6 vs. 19.5%; p=0.225). MWA was associated with shorter ablation times (median 12 vs. 29 minutes; p<0.001) and less frequent use of general anesthesia (47 vs. 84%; p<0.001)[85].

A multicenter randomized trial conducted across five centers in Japan compared MWA and RFA in patients with up to four HCC lesions measuring ≤4 cm. At two-year follow-up, MWA was associated with a significantly lower rate of local tumor progression compared with RFA (16.4 vs 30.4%; p=0.007). Despite this improvement in local control, no significant differences were observed between groups in overall survival or intrahepatic and extrahepatic recurrence-free survival. Both techniques demonstrated favorable safety profiles, with very low rates of severe complications reported[206]. These findings indicate that MWA may provide superior local tumor control compared with RFA in lesions up to 4 cm. However, this advantage does not appear to translate into improved survival outcomes.

Recommendation 33: MWA yields outcomes comparable to radiofrequency ablation for HCC lesions up to 3 cm and may be preferred for tumors up to 4 cm or those adjacent to large vessels because of its lower susceptibility to heat-sink effects.

Evidence Level: Moderate

Recommendation Grade: Weak

What is the current role of irreversible electroporation in the treatment of HCC?

Irreversible electroporation (IRE) is a non-thermal ablative technique that induces cell death by delivering high-voltage electrical pulses, permanently disrupting cell membrane integrity and subsequent apoptosis[122,161]. Because it does not rely on thermal energy, IRE preserves the extracellular matrix and critical structures such as bile ducts and blood vessels, distinguishing it from thermal modalities such as RFA and MWA.

This property makes IRE particularly attractive for tumors located in challenging anatomical sites, including perivascular and peribiliary regions, where the heat-sink effect or risk of thermal injury may limit the effectiveness or safety of conventional ablation techniques[73,161]. In these scenarios, IRE may allow treatment of lesions that would otherwise be considered unsuitable for percutaneous ablation.

Available evidence on IRE in HCC is limited, consisting primarily of small series. These studies suggest that the technique is feasible and can be performed with acceptable safety profiles in selected patients with unresectable tumors[122]. However, local recurrence remains a concern, particularly in larger lesions, where incomplete ablation appears more frequent[44,73].

The procedure also has specific technical considerations and risks. Because of the delivery of electrical pulses, IRE requires general anesthesia with neuromuscular blockade and cardiac synchronization to minimize the risk of arrhythmias and muscle contractions.

Recommendation 34: Although IRE can be used to treat centrally located, unresectable HCC lesions near bile ducts and major vessels, there is currently insufficient evidence to support its routine clinical use.

Evidence Level: Low

Recommendation Grade: Weak

What is the current evidence supporting the combination of systemic targeted therapy or immunotherapy with intra-arterial therapies or thermal ablation in patients with HCC?

The combination of locoregional and systemic therapies in HCC has been investigated based on biological rationale and evolving clinical evidence. In the context of TACE, embolization-induced hypoxia leads to upregulation of angiogenic pathways, providing a rationale for combining intra-arterial therapy with anti-angiogenic agents. Early randomized studies evaluating TACE combined with sorafenib, however, failed to demonstrate consistent improvements in objective response or overall survival compared with TACE alone, and this strategy was not incorporated into standard practice[65,111,124,156,183, 205].

More recent trials using newer systemic agents have shown more promising results. In the phase III LAUNCH trial, the combination of lenvatinib with TACE demonstrated significantly improved outcomes compared with lenvatinib alone in patients with advanced HCC. Objective response rate was higher with combination therapy (54.1 vs. 25%; p<0.001), with corresponding improvements in progression-free survival (10.6 vs 6.4 months; p<0.001) and overall survival (17.8 vs. 11.5 months; HR=0.45; p<0.001)[173]. These findings support the potential role of combined locoregional–systemic strategies in selected patients, including as part of downstaging or conversion approaches.

The integration of immune-based therapies with TACE has also been evaluated in recent phase III trials. In the EMERALD-1 study, the combination of durvalumab plus bevacizumab with TACE significantly improved progression-free survival compared with TACE alone, whereas durvalumab combined with TACE without VEGF inhibition did not show benefit, highlighting the importance of anti-angiogenic modulation in this setting[194]. Similarly, the LEAP-012 trial demonstrated improved progression-free survival with lenvatinib plus pembrolizumab combined with TACE compared with TACE plus placebo, although this was accompanied by higher rates of grade 3–4 adverse events[113].

Additional evidence from a meta-analysis of phase III trials, including EMERALD-1, LEAP-012, and TALENTACE, demonstrated that the combination of TACE with immunotherapy and targeted therapy significantly improved progression-free survival compared with TACE alone (HR=0.69; 95%CI 0.60–0.79) and increased objective response rates (odds ratio (OR)=1.83; 95%CI 1.45–2.31). However, overall survival data remain immature, with no statistically significant difference observed at the time of analysis. This benefit was accompanied by increased toxicity, with higher rates of grade 3–5 adverse events (RR=1.88; 95%CI 1.48–2.40) and serious adverse events (RR=1.65; 95%CI 1.31–2.07) in the combination groups[226].

These findings suggest a potential role for integrated locoregional–systemic strategies, particularly in intermediate-stage disease, but several uncertainties remain, including optimal patient selection, therapy sequencing, and management of treatment-related toxicity. In addition, considerations related to cost, access, and reimbursement are particularly relevant in healthcare systems with constrained resources, such as in Brazil, and may influence the applicability of these strategies in routine practice.

In contrast, evidence supporting the combination of systemic therapy or immunotherapy with thermal ablation (RFA or MWA) is limited. Available data are derived primarily from early-phase studies and translational research, without phase III trials demonstrating a survival benefit. As a result, adding immunotherapy to curative-intent ablation remains investigational and has not been incorporated into standard treatment algorithms[82].

Recommendation 35: Combination strategies involving TACE with lenvatinib-based or immune-based systemic therapy may be considered in selected patients after multidisciplinary evaluation, particularly when the goal is to improve tumor response and progression-free survival, while recognizing the higher risk of treatment-related adverse events and the still-limited mature overall survival data. Adding immunotherapy to thermal ablation should be considered investigational.

Evidence Level: Low

Recommendation Grade: Weak

When should external beam radiation therapy be used for HCC?

External beam radiotherapy (EBRT) has evolved considerably with advances in imaging, treatment planning, and radiation delivery. Modern techniques such as intensity-modulated radiotherapy (IMRT), stereotactic body radiotherapy (SBRT), and proton beam therapy allow highly conformal dose delivery while sparing non-tumoral liver parenchyma. These developments have reduced the risk of radiation-induced liver disease and enabled the safe administration of ablative doses, with reported rates of severe toxicity below 5% in selected patients[10,102].

In early-stage HCC (BCLC 0–A), SBRT has emerged as a potential ablative option for patients who are not candidates for surgical resection, liver transplantation, or thermal ablation. This includes patients with unfavorable tumor location, impaired liver function, or significant comorbidities. SBRT is particularly useful for lesions that are difficult to access percutaneously, such as tumors adjacent to the diaphragm, gallbladder, or major vascular structures, and for lesions larger than those typically treated with ablation. Reported outcomes show high local control rates, particularly in tumors measuring 1-6 cm, among patients with preserved liver function[10,119,231]. A meta-analysis reported local control rates approaching 86% and a 3-year overall survival of approximately 48% in tumors smaller than 5 cm[185].

Comparative evidence suggests that EBRT may achieve outcomes comparable to those of other locoregional therapies, including TACE, TARE, and thermal ablation, in selected patients who are not candidates for curative-intent interventions[10,65,170,231].

Beyond early-stage disease, EBRT has been used in a variety of clinical scenarios, including treatment of lesions not amenable to other locoregional therapies, consolidation after incomplete response to TACE or TARE, and management of local recurrence. It may also be considered as a bridging strategy in patients awaiting liver transplantation when other locoregional options are not feasible[184].

In advanced disease, radiotherapy has been investigated in combination with systemic therapy. The phase III RTOG 1112 trial evaluated SBRT followed by sorafenib in patients with advanced HCC, most of whom had macrovascular invasion. The combination resulted in a higher vascular response rate compared with sorafenib alone (38 vs. 9%; p<0.001), suggesting improved local control of vascular tumor thrombus[50]. However, the impact on overall survival and progression-free survival remains less clearly defined, and further studies incorporating current systemic therapies are needed.

Recommendation 36: In HCC, external beam radiation therapy may be used as a locoregional treatment in patients who are not candidates for resection, transplantation, or thermal ablation because of comorbidities, limited liver reserve, or unfavorable tumor location, and it may also be used for consolidation after incomplete response following embolization or ablation.

Evidence Level: Moderate

Recommendation Grade: Strong

DISCUSSION

This multidisciplinary consensus synthesizes current evidence and expert judgment to provide structured guidance on liver resection, liver transplantation, and locoregional therapies for HCC. By addressing key clinical questions across the therapeutic continuum, this document highlights principles of patient selection, integration of curative-intent strategies, and the complementary roles of surgical and locoregional approaches. The recommendations support coherent, multidisciplinary decision-making across multiple scenarios.

Developing consensus documents is particularly relevant in clinical fields in which high-quality evidence is heterogeneous and not uniformly applicable across different healthcare settings. This is especially true for HCC, a biologically and clinically complex disease that frequently requires coordinated decision-making among multiple specialties, including hepatology, hepatopancreatobiliary surgery, liver transplantation, medical oncology, interventional radiology, diagnostic imaging, and endoscopy. HCC management involves the interaction of tumor-related factors, underlying liver dysfunction, and patient-specific characteristics, resulting in a broad and evolving therapeutic arsenal. As a consequence of this multidimensional complexity and marked clinical heterogeneity, it is challenging to comprehensively evaluate treatment pathways through randomized controlled trials, and many clinically relevant questions remain insufficiently addressed by high-level evidence. While clinical studies provide essential information, their results do not always translate directly to real-world practice. This limitation is particularly relevant in countries such as Brazil, where much of the available evidence is derived from external cohorts and may not fully reflect local realities, including transplant waiting-list dynamics, resource availability, regulatory requirements, procedural costs, and patient preferences. In this context, consensus statements and guidance documents play a critical role by allowing expert interpretation of evidence, balancing risks and benefits, and weighing advantages and limitations of different therapeutic strategies, thereby supporting individualized and multidisciplinary clinical decision-making rather than prescriptive or rigid treatment algorithms[214].

Important limitations remain in the current evidence base for HCC treatment. Comparative data between therapeutic modalities are frequently derived from observational studies, and optimal sequencing, timing, and combination of therapies continue to evolve. In particular, the increasing use of combined strategies—integrating resection, transplantation, locoregional treatments, and systemic therapies—underscores the need for

CC BY

further research to define optimal treatment algorithms, patient selection criteria, and timing of intervention. Future studies should focus on refining these strategies to improve outcomes while minimizing risk, thereby strengthening the evidence to inform future updates to consensus recommendations.

CONCLUSION

This multidisciplinary consensus provides structured, evidence-based guidance on liver resection, liver transplantation, and locoregional therapies in HCC management. By addressing key clinical questions about patient selection, therapeutic indications, and integration of curative and locoregional strategies, these recommendations aim to support consistent, informed decision-making in daily clinical practice and to optimize outcomes for patients eligible for potentially curative treatment.

AUTHORS' CONTRIBUTION

Coimbra FJF: Conceptualization, Data analysis, Methodology, Writing – original draft, Writing – review & editing. Oliveira AF: Conceptualization, Data analysis, Methodology, Writing – original draft, Writing – review & editing. Tustumi F: Data analysis, Methodology, Writing – review & editing. Godoy AL: Investigation, Writing – original draft, Writing – review & editing; Fernandes PHS: Investigation, Writing – original draft, Writing – review & editing. Feitosa Neto H: Investigation, Writing – original draft, Writing – review & editing. Pinheiro RN: Investigation, Writing – original draft, Writing – review & editing. Boin IFSF: Investigation, Writing – original draft, Writing – review & editing. Andraus W: Investigation, Writing – original draft, Writing – review & editing. Amaral PCG: Investigation, Writing – original draft, Writing – review & editing. Mello CEB: Investigation, Writing – original draft, Writing – review & editing. Braun AC: Investigation, Writing – original draft, Writing – review & editing. Braghiroli MI: Investigation, Writing – original draft, Writing – review & editing. Bredt LC: Investigation, Writing – original draft, Writing – review & editing. Caparroz C: Investigation, Writing – original draft, Writing – review & editing. Carrilho FJ: Investigation, Writing – original draft, Writing – review & editing. Cunha GM: Investigation, Writing – original draft, Writing – review & editing. Diniz AL: Investigation, Writing – original draft, Writing – review & editing. Forte DN: Investigation, Writing – original draft, Writing – review & editing. Garcia JHP: Investigation, Writing – original draft, Writing – review & editing. Genzini T: Investigation, Writing – original draft, Writing – review & editing. Correia MM: Investigation, Writing – original draft, Writing – review & editing. Oliveira CVC: Investigation, Writing – original draft, Writing – review & editing. Kalil AN: Investigation, Writing – original draft, Writing – review & editing. Lima AS: Investigation, Writing – original draft, Writing – review & editing. Martins GLP: Investigation, Writing – original draft, Writing – review & editing. Rocha CM: Investigation, Writing – original draft, Writing – review & editing. Menezes MR: Investigation, Writing – original draft, Writing – review & editing. Motta-Leal-Filho JM: Investigation, Writing – original draft, Writing – review & editing. Murad Júnior M: Investigation, Writing – original draft, Writing – review & editing. Peixoto RD: Investigation, Writing – original draft, Writing – review & editing. Pinheiro RS: Investigation, Writing – original draft, Writing – review & editing. Ribeiro HSC: Investigation, Writing – original draft, Writing – review & editing. Martins MR: Investigation, Writing – original draft, Writing – review & editing. Rocha Filho DR: Investigation, Writing – original draft, Writing – review & editing. Rosa AA: Investigation, Writing – original draft, Writing – review & editing. Szutan LA: Investigation, Writing – original draft, Writing – review & editing. Torres OJM: Investigation, Writing – original draft, Writing – review & editing. D'Albuquerque LAC: Investigation, Writing – original draft, Writing – review & editing. Mattos AA: Investigation, Writing – original draft, Writing – review & editing. Coutinho AK: Investigation, Writing – original draft, Writing – review & editing. Herman P: Investigation, Writing – original draft, Writing – review & editing. Rezende MB: Investigation, Writing – original draft, Writing – review & editing.

DATA AVAILABILITY STATEMENT

The datasets generated and/or analyzed during the current study are available from the corresponding author upon reasonable request.

The information regarding the investigation, methodology, and data analysis of the article is archived under the authors' responsibility.

REFERENCES

1. Abecassis MM, Fisher RA, Olthoff KM, Freise CE, Rodrigo DR, Samstein B, et al. Complications of living donor hepatic lobectomy--a comprehensive report. Am J Transplant. 2012;12(5):1208-17. https://doi.org/10.1111/j.1600-6143.2011.03972.x
2. Abu-Gazala S, Olthoff KM. Current status of living donor liver transplantation in the United States. Annu Rev Med. 2019;70:225-38. https://doi.org/10.1146/annurev-med-051517-125454
3. Hilal MA, Aldrighetti L, Dagher I, Edwin B, Troisi RI, Alikhanov R, et al. The southampton consensus guidelines for laparoscopic liver surgery: from indication to implementation. Ann Surg. 2018;268(1):11-8. https://doi.org/10.1097/SLA.0000000000002524
4. Agopian VG, Harlander-Locke MP, Ruiz RM, Klintmalm GB, Senguttuvan S, Florman SS, et al. Impact of pretransplant bridging locoregional therapy for patients with hepatocellular carcinoma within milan criteria undergoing liver transplantation: analysis of 3,601 patients from the US Multicenter HCC Transplant Consortium. Ann Surg. 2017;266(3):525-35. https://doi.org/10.1097/SLA.0000000000002381
5. Akula V, Chen L, Acikgoz Y, Klein K, Yavuz BG, Cevik L, et al. Neoadjuvant immune checkpoint inhibitors for hepatocellular carcinoma. NPJ Precis Oncol. 2025;9(1):60. https://doi.org/10.1038/s41698-025-00846-4
6. Al-Adra DP, Hammel L, Roberts J, Woodle ES, Levine D, Mandelbrot D, et al. Pretransplant solid organ malignancy and organ transplant candidacy: A consensus expert opinion statement. Am J Transplant. 2021;21(2):460-74. https://doi.org/10.1111/ajt.16318
7. Al-Ameri A, Yu X, Zheng S. Predictors of post-recurrence survival in hepatocellular carcinoma patients following liver transplantation: Systematic review and meta-analysis. Transplant Rev. 2022;36(1):100676. https://doi.org/10.1016/j.trre.2021.100676

8. Allaire M, Goumard C, Lim C, Le Cleach A, Wagner M, Scatton O. New frontiers in liver resection for hepatocellular carcinoma. JHEP Rep. 2020;2(4):100134. https://doi.org/10.1016/j.jhepr.2020.100134
9. Andraus W. Liver transplantation in Brazil: the urgent need of a new allocation system for the exceptions in MELD score. Arq Gastroenterol. 2020;57(1):1-2. https://doi.org/10.1590/S0004-2803.202000000-01
10. Apisarnthanarax S, Barry A, Cao M, Czito B, DeMatteo R, Drinane M, et al. External beam radiation therapy for primary liver cancers: An ASTRO Clinical Practice Guideline. Pract Radiat Oncol. 2022;12(1):28-51. https://doi.org/10.1016/j.prro.2021.09.004
11. Azoulay D, Castaing D, Krissat J, Smail A, Hargreaves GM, Lemoine A, et al. Percutaneous portal vein embolization increases the feasibility and safety of major liver resection for hepatocellular carcinoma in injured liver. Ann Surg. 2000;232(5):665-72.https://doi.org/10.1097/00000658-200011000-00008
12. Bargellini I, Lorenzoni V, Lorenzoni G, Scalise P, Andreozzi G, Bozzi E, et al. Duration of response after DEB-TACE compared to lipiodol-TACE in HCC-naïve patients: a propensity score matching analysis. Eur Radiol. 2021;31(10):7512-22. https://doi.org/10.1007/s00330-021-07905-x
13. Barron JO, Orabi D, Moro A, Quintini C, Berber E, Aucejo FN, et al. Validation of the IWATE criteria as a laparoscopic liver resection difficulty score in a single North American cohort. Surg Endosc. 2022;36(5):3601-9. https://doi.org/10.1007/s00464-021-08561-4
14. Berardi G, Morise Z, Sposito C, Igarashi K, Panetta V, Simonelli I, et al. Development of a nomogram to predict outcome after liver resection for hepatocellular carcinoma in Child-Pugh B cirrhosis. J Hepatol. 2020;72(1):75-84. https://doi.org/10.1016/j.jhep.2019.08.032
15. Berzigotti A, Reig M, Abraldes JG, Bosch J, Bruix J. Portal hypertension and the outcome of surgery for hepatocellular carcinoma in compensated cirrhosis: a systematic review and meta-analysis. Hepatology. 2015;61(2):526-36. https://doi.org/10.1002/hep.27431
16. Brattström C, Granath F, Edgren G, Smedby KE, Wilczek HE. Overall and cause-specific mortality in transplant recipients with a pretransplantation cancer history. Transplantation. 2013;96(3):297-305. https://doi.org/10.1097/TP.0b013e31829854b7
17. Brazilian Association of Organ Transplantation (ABTO). Brazilian Transplant Registry: transplant statistics in Brazil and by state (2017–2024) [Internet]. São Paulo: ABTO; 2024 [cited 2026 Apr 3]. Available from: https://site.abto.org.br/wp-content/uploads/2025/05/rbt-n4-2024-populacao.pdf
18. Brazilian Association of Organ Transplantation (ABTO). Transplant statistics in Brazil and by state (2016-2023) [Internet]. São Paulo: ABTO; 2024 [cited 2026 Apr 3]. Available from: https://site.abto.org.br/wp-content/uploads/2024/03/RBT_2023-Populacao_Atualizado.pdf
19. Brazil. Ordinance No. 656, of April 1, 2020 [Internet]. Brasília: Ministry of Health; 2020 [cited 2026 Apr 3]. Available from: https://bvsms.saude.gov.br/bvs/saudelegis/gm/2020/prt0656_03_04_2020.htm
20. Bruix J, Takayama T, Mazzaferro V, Chau GY, Yang J, Kudo M, et al. Adjuvant sorafenib for hepatocellular carcinoma after resection or ablation (STORM): a phase 3, randomised, double-blind, placebo-controlled trial. Lancet Oncol. 2015;16(13):1344-54. https://doi.org/10.1016/S1470-2045(15)00198-9
21. Burak KW. Prognosis in the early stages of hepatocellular carcinoma: Predicting outcomes and properly selecting patients for curative options. Can J Gastroenterol. 2011;25(9):482-4.https://doi.org/10.1155/2011/302457
22. Burrel M, Reig M, Forner A, Barrufet M, Lope CR, Tremosini S, et al. Survival of patients with hepatocellular carcinoma treated by transarterial chemoembolisation (TACE) using Drug Eluting Beads. Implications for clinical practice and trial design. J Hepatol. 2012;56(6):1330-5. https://doi.org/10.1016/j.jhep.2012.01.008
23. Bzeizi KI, Arabi M, Jamshidi N, Albenmousa A, Sanai FM, Al-Hamoudi W, et al. Conventional transarterial chemoembolization versus drug-eluting beads in patients with hepatocellular carcinoma: a systematic review and meta-analysis. Cancers. 2021;13(24):6172. https://doi.org/10.3390/cancers13246172
24. Cao S, Zou Y, Lyu T, Fan Z, Guan H, Song L, et al. Long-term outcomes of combined transarterial chemoembolization and radiofrequency ablation versus RFA monotherapy for single hepatocellular carcinoma ≤3 cm: emphasis on local tumor progression. Int J Hyperthermia. 2022;39(1):1-7. https://doi.org/10.1080/02656736.2021.1998660
25. Caringi S, Delvecchio A, Conticchio M, Ratti F, Magistri P, Belli A, et al. Robotic liver resection for hepatocellular carcinoma: a multicenter case series. Cancers. 2025;17(3):415. https://doi.org/10.3390/cancers17030415
26. Cauchy F, Soubrane O, Belghiti J. Liver resection for HCC: patient's selection and controversial scenarios. Best Pract Res Clin Gastroenterol. 2014;28(5):881-96. https://doi.org/10.1016/j.bpg.2014.08.013
27. Cavalcante LN, Queiroz RMT, Paz CLDSL, Lyra AC. Better living donor liver transplantation patient survival compared to deceased donor - a systematic review and meta-analysis. Arq Gastroenterol. 2022;59(1):129-36. https://doi.org/10.1590/S0004-2803.202200001-22
28. Chagas AL, Felga GEG, Diniz MA, Silva RF, Mattos AA, Silva RCMA, et al. Hepatocellular carcinoma recurrence after liver transplantation in a Brazilian multicenter study: clinical profile and prognostic factors of survival. Eur J Gastroenterol Hepatol. 2019;31(9):1148-56. https://doi.org/10.1097/MEG.0000000000001448
29. Chagas AL, Mattos AA, Diniz MA, Felga GEG, Boin IFSF, Silva RCMA, et al. Impact of Brazilian expanded criteria for liver transplantation in patients with hepatocellular carcinoma: a multicenter study. Ann Hepatol. 2021;22:100294. https://doi.org/10.1016/j.aohep.2020.100294
30. Chan MY, She WH, Dai WC, Tsang SHY, Chok KSH, Chan ACY, et al. Prognostic value of preoperative alpha-fetoprotein (AFP) level in patients receiving curative hepatectomy: an analysis of 1,182 patients in Hong Kong. Transl Gastroenterol Hepatol. 2019;4:52. https://doi.org/10.21037/tgh.2019.06.07
31. Chan SL, Sun HC, Xu Y, Zeng H, El-Serag HB, Lee JM, et al. The Lancet Commission on addressing the global hepatocellular carcinoma burden: comprehensive strategies from prevention to treatment. Lancet. 2025;406(10504):731-78. https://doi.org/10.1016/S0140-6736(25)01042-6
32. Charrière B, Maulat C, Suc B, Muscari F. Contribution of alpha-fetoprotein in liver transplantation for hepatocellular

carcinoma. World J Hepatol. 2016;8(21):881-90. https://doi.org/10.4254/wjh.v8.i21.881
33. Chen Liver Transplantation, Martinelli E, Cheng AL, Pentheroudakis G, Qin S, Bhattacharyya GS, et al. Pan-Asian adapted ESMO Clinical Practice Guidelines for the management of patients with intermediate and advanced/relapsed hepatocellular carcinoma: a TOS-ESMO initiative endorsed by CSCO, ISMPO, JSMO, KSMO, MOS and SSO. Ann Oncol. 2020;31(3):334-51. https://doi.org/10.1016/j.annonc.2019.12.001
34. Cho YK, Kim JK, Kim MY, Rhim H, Han JK. Systematic review of randomized trials for hepatocellular carcinoma treated with percutaneous ablation therapies. Hepatology. 2009;49(2):453-9. https://doi.org/10.1002/hep.22648
35. Cho YK, Kim JK, Kim WT, Chung JW. Hepatic resection versus radiofrequency ablation for very early stage hepatocellular carcinoma: a Markov model analysis. Hepatology. 2010;51(4):1284-90. https://doi.org/10.1002/hep.23466
36. Chow PKH, Gandhi M, Tan SB, Khin MW, Khasbazar A, Ong J, et al. SIRveNIB: selective internal radiation therapy versus sorafenib in asia-pacific patients with hepatocellular carcinoma. J Clin Oncol. 2018;36(19):1913-21. https://doi.org/10.1200/JCO.2017.76.0892
37. Cipriani F, Fantini C, Ratti F, Lauro R, Tranchart H, Halls M, et al. Laparoscopic liver resections for hepatocellular carcinoma. Can we extend the surgical indication in cirrhotic patients? Surg Endosc. 2018;32(2):617-26. https://doi.org/10.1007/s00464-017-5711-x
38. Ciria R, Ayllon MD, Briceño J. Difficulty scores in laparoscopic liver surgery-getting closer to a powerful and necessary tool. Hepatobiliary Surg Nutr. 2019;8(4):428-30. https://doi.org/10.21037/hbsn.2019.02.11
39. Citterio D, Facciorusso A, Sposito C, Rota R, Bhoori S, Mazzaferro V. Hierarchic interaction of factors associated with liver decompensation after resection for hepatocellular carcinoma. JAMA Surg. 2016;151(9):846-53. https://doi.org/10.1001/jamasurg.2016.1121
40. Clavien PA, Lesurtel M, Bossuyt PM, Gores GJ, Langer B, Perrier A, et al. Recommendations for liver transplantation for hepatocellular carcinoma: an international consensus conference report. Lancet Oncol. 2012;13(1):e11-22. https://doi.org/10.1016/S1470-2045(11)70175-9
41. Coimbra FJF, Godoy AL, Fernandes PHS, Castro Neto HFE, Pinheiro RN, Boin IFSF, et al. Prevention, surveillance, and early detection of hepatocellular carcinoma - a Brazilian multidisciplinary consensus. Arq Bras Cir Dig. 2026;39:e1947. https://doi.org/10.1590/0102-672020260000018e1947
42. Colmenero J, Tabrizian P, Bhangui P, Pinato DJ, Rodríguez-Perálvarez ML, Sapisochin G, et al. De Novo malignancy after liver transplantation: risk assessment, prevention, and management-guidelines from the ILTS-SETH Consensus Conference. Transplantation. 2022;106(1):e30-e45. https://doi.org/10.1097/TP.0000000000003998
43. Cottone C, Polanco NAP, Bhamidimarri KR. Transplant of elderly patients: is there an upper age cutoff? Clin Liver Dis. 2021;25(1):209-27. https://doi.org/10.1016/j.cld.2020.09.001
44. Cribbs KA, Baisley WT, Lahue BJ, Peddu P. Clinical and safety outcomes in unresectable, very early and early-stage hepatocellular carcinoma following Irreversible Electroporation (IRE) and Transarterial Chemoembolization (TACE): A systematic literature review and meta-analysis. PLoS One. 2025;20(4):e0322113. https://doi.org/10.1371/journal.pone.0322113
45. Crocetti L, Bozzi E, Scalise P, Bargellini I, Lorenzoni G, Ghinolfi D, et al. Locoregional treatments for bridging and downstaging HCC to liver transplantation. Cancers. 2021;13(21):5558. https://doi.org/10.3390/cancers13215558
46. Cucchetti A, Ercolani G, Vivarelli M, Cescon M, Ravaioli M, La Barba G, et al. Impact of model for end-stage liver disease (MELD) score on prognosis after hepatectomy for hepatocellular carcinoma on cirrhosis. Liver Transpl. 2006;12(6):966-71. https://doi.org/10.1002/lt.20761
47. Cucchetti A, Piscaglia F, Cescon M, Colecchia A, Ercolani G, Bolondi L, et al. Cost-effectiveness of hepatic resection versus percutaneous radiofrequency ablation for early hepatocellular carcinoma. J Hepatol. 2013;59(2):300-7. https://doi.org/10.1016/j.jhep.2013.04.009
48. Cucchetti A, Piscaglia F, Cescon M, Ercolani G, Terzi E, Bolondi L, et al. Conditional survival after hepatic resection for hepatocellular carcinoma in cirrhotic patients. Clin Cancer Res. 2012;18(16):4397-405. https://doi.org/10.1158/1078-0432.CCR-11-2663
49. D'Arcy ME, Coghill AE, Lynch CF, Koch LA, Li J, Pawlish KS, et al. Survival after a cancer diagnosis among solid organ transplant recipients in the United States. Cancer. 2019;125(6):933-42. https://doi.org/10.1002/cncr.31782
50. Dawson LA, Winter KA, Knox JJ, Zhu AX, Krishnan S, Guha C, et al. Stereotactic body radiotherapy vs sorafenib alone in hepatocellular carcinoma: the NRG Oncology/RTOG 1112 phase 3 randomized clinical trial. JAMA Oncol. 2025;11(2):136-44. https://doi.org/10.1001/jamaoncol.2024.5403
51. de'Angelis N, Landi F, Carra MC, Azoulay D. Managements of recurrent hepatocellular carcinoma after liver transplantation: A systematic review. World J Gastroenterol. 2015;21(39):11185-98. https://doi.org/10.3748/wjg.v21.i39.11185
52. Franchis R, Bosch J, Garcia-Tsao G, Reiberger T, Ripoll C; Baveno VII Faculty. Baveno VII - Renewing consensus in portal hypertension. J Hepatol. 2022;76(4):959-74. https://doi.org/10.1016/j.jhep.2021.12.022. Erratum in: J Hepatol. 2022;77(1):271. https://doi.org/10.1016/j.jhep.2022.03.024
53. Delis SG, Bakoyiannis A, Dervenis C, Tassopoulos N. Perioperative risk assessment for hepatocellular carcinoma by using the MELD score. J Gastrointest Surg. 2009;13(12):2268-75. https://doi.org/10.1007/s11605-009-0977-5
54. Simone P, Precisi A, Lai Q, Ducci J, Campani D, Marchetti P, et al. Everolimus mitigates the risk of hepatocellular carcinoma recurrence after liver transplantation. Cancers. 2024;16(7):1243. https://doi.org/10.3390/cancers16071243
55. DiNorcia J, Florman SS, Haydel B, Tabrizian P, Ruiz RM, Klintmalm GB, et al. Pathologic response to pretransplant locoregional therapy is predictive of patient outcome after liver transplantation for hepatocellular carcinoma: analysis from the US Multicenter HCC Transplant Consortium. Ann Surg. 2020;271(4):616-24. https://doi.org/10.1097/SLA.0000000000003253
56. Dolnikov S, Adam R, Cherqui D, Allard MA. Liver transplantation in elderly patients: what do we know at the

beginning of 2020? Surg Today. 2020;50(6):533-9. https://doi.org/10.1007/s00595-020-01996-7
57. Durand F, Levitsky J, 98. Cauchy F, Gilgenkrantz H, Soubrane O, Francoz C. Age and liver transplantation. J Hepatol. 2019;70(4):745-58. https://doi.org/10.1016/j.jhep.2018.12.009
58. Ebara M, Kita K, Nagato Y, Yoshikawa M, Sugiura N, Ohto M. [Percutaneous ethanol injection (PEI) for small hepatocellular carcinoma]. Gan To Kagaku Ryoho. 1993;20(7):884-8.
59. Eguchi S, Kanematsu T, Arii S, Okazaki M, Okita K, Omata M, et al. Comparison of the outcomes between an anatomical subsegmentectomy and a non-anatomical minor hepatectomy for single hepatocellular carcinomas based on a Japanese nationwide survey. Surgery. 2008;143(4):469-75. https://doi.org/10.1016/j.surg.2007.12.003
60. Enestvedt CK, Orloff SL. Locoregional therapy, pathologic response, and HCC recurrence after liver transplantation: highlighting success and looking toward the future. Ann Surg. 2020;271(4):625-6. https://doi.org/10.1097/SLA.0000000000003712
61. Engels EA, Haber G, Hart A, Lynch CF, Li J, Pawlish KS, et al. Solid organ transplantation and survival among individuals with a history of cancer. Cancer Epidemiol Biomarkers Prev. 2021;30(7):1312-9. https://doi.org/10.1158/1055-9965.EPI-21-0044
62. Eskens FA, van Erpecum KJ, Jong KP, van Delden OM, Klumpen HJ, Verhoef C, et al. Hepatocellular carcinoma: Dutch guideline for surveillance, diagnosis and therapy. Neth J Med. 2014;72(6):299-304.
63. European Association for the Study of the Liver. EASL Clinical Practice Guidelines: Liver transplantation. J Hepatol. 2016;64(2):433-85. https://doi.org/10.1016/j.jhep.2015.10.006
64. European Association for the Study of the Liver. EASL Clinical Practice Guidelines: Management of hepatocellular carcinoma. J Hepatol. 2018;69(1):182-236. https://doi.org/10.1016/j.jhep.2018.03.019
65. European Association for the Study of the Liver. EASL Clinical Practice Guidelines on the management of hepatocellular carcinoma. J Hepatol. 2025;82(2):315-74. https://doi.org/10.1016/j.jhep.2024.08.028
66. Exposito MJ, Akce M, Alvarez J, Assenat E, Balart L, Baron A, et al. Abstract No. 526 CheckMate-9DX: phase 3, randomized, double-blind study of adjuvant nivolumab vs placebo for patients with hepatocellular carcinoma (HCC) at high risk of recurrence after curative resection or ablation. J Vasc Interv Radiol. 2019;30(3 Suppl.):S227-S228. https://doi.org/10.1016/j.jvir.2018.12.607
67. Fang Y, Chen W, Liang X, Li D, Lou H, Chen R, et al. Comparison of long-term effectiveness and complications of radiofrequency ablation with hepatectomy for small hepatocellular carcinoma. J Gastroenterol Hepatol. 2014;29(1):193-200. https://doi.org/10.1111/jgh.12441
68. Felli E, Cillo U, Pinna AD, De Carlis L, Ercolani G, Santoro R, et al. Salvage liver transplantation after laparoscopic resection for hepatocellular carcinoma: a multicenter experience. Updates Surg. 2015;67(2):215-22. https://doi.org/10.1007/s13304-015-0323-2
69. Ferla F, Lauterio A, De Carlis R, Di Sandro S, Petrucciani N, Benuzzi L, et al. Comment on the article "Age and liver transplantation". J Hepatol. 2019;70(6):1305-6. https://doi.org/10.1016/j.jhep.2019.02.007
70. Ferreira GF, Haddad LBDP, Andrade LGMD, Sandes-Freitas TVD, Manfro RC, Atik FA, et al. Analysis of the Brazilian Transplant Registry 2024. Braz J Transplant. 2025;28:e4925. https://doi.org/10.53855/bjt.v28i1.740_PORT
71. Fonseca LG, Chen ATC, Oliveira IS, Chagas AL, Kruger JAP, Carrilho FJ. Brazilian landscape of hepatocellular carcinoma. JCO Glob Oncol. 2023;9:e2200416. https://doi.org/10.1200/GO.22.00416
72. Forner A, Reig ME, Lope CR, Bruix J. Current strategy for staging and treatment: the BCLC update and future prospects. Semin Liver Dis. 2010;30(1):61-74. https://doi.org/10.1055/s-0030-1247133
73. Freeman E, Cheung W, Kavnoudias H, Majeed A, Kemp W, Roberts SK. Irreversible electroporation for hepatocellular carcinoma: longer-term outcomes at a single centre. Cardiovasc Intervent Radiol. 2021;44(2):247-53. https://doi.org/10.1007/s00270-020-02666-4
74. Garin E, Tselikas L, Guiu B, Chalaye J, Rolland Y, Baere T, et al. Long-term overall survival after selective internal radiation therapy for locally advanced hepatocellular carcinomas: updated analysis of DOSISPHERE-01 Trial. J Nucl Med. 2024;65(2):264-9. https://doi.org/10.2967/jnumed.123.266211
75. Geissler EK, Schnitzbauer AA, Zülke C, Lamby PE, Proneth A, Duvoux C, et al. Sirolimus use in liver transplant recipients with hepatocellular carcinoma: a randomized, multicenter, open-label phase 3 trial. Transplantation. 2016;100(1):116-25. https://doi.org/10.1097/TP.0000000000000965
76. Gelli M, Sebagh M, Porcher R, Romanelli E, Vibert E, Cunha AS, et al. Liver resection for early hepatocellular carcinoma: preoperative predictors of non transplantable recurrence and implications for treatment allocation. Ann Surg. 2020;272(5):820-6. https://doi.org/10.1097/SLA.0000000000004259
77. Genzini T, Rodrigues MG, Almeida TN, Danziere FR, Fonseca LEPD, Genzini MC, et al. Liver transplantation in patients over 70 years old. Arq Bras Cir Dig. 2025;38:e1894. https://doi.org/10.1590/0102-67202025000025e1894
78. Giard JM, Mehta N, Dodge JL, Roberts JP, Yao FY. Alpha-fetoprotein slope >7.5 ng/mL per month predicts microvascular invasion and tumor recurrence after liver transplantation for hepatocellular carcinoma. Transplantation. 2018;102(5):816-22. https://doi.org/10.1097/TP.0000000000002094
79. Glantzounis GK, Paliouras A, Stylianidi MC, Milionis H, Tzimas P, Roukos D, et al. The role of liver resection in the management of intermediate and advanced stage hepatocellular carcinoma. A systematic review. Eur J Surg Oncol. 2018;44(2):195-208. https://doi.org/10.1016/j.ejso.2017.11.022
80. Goldaracena N, Mehta N, Scalera I, Sposito C, Atenafu EG, Yao FY, et al. Multicenter validation of a score to predict prognosis after the development of HCC recurrence following liver transplantation. HPB. 2019;21(6):731-8. https://doi.org/10.1016/j.hpb.2018.10.005
81. Goyal P, Salem R, Mouli SK. Role of interventional oncology in hepatocellular carcinoma: Future best practice beyond current guidelines. Br J Radiol. 2022;95(1138):20220379. https://doi.org/10.1259/bjr.20220379

82. Greten TF, Lai CW, Li G, Staveley-O'Carroll KF. Targeted and immune-based therapies for hepatocellular carcinoma. Gastroenterology. 2019;156(2):510-24. https://doi.org/10.1053/j.gastro.2018.09.051
83. Gunay Y, Guler N, Yaprak O, Dayangac M, Akyildiz M, Altaca G, et al. Living donor liver transplantation outcomes for hepatocellular carcinoma beyond Milan or UCSF criteria. Indian J Surg. 2015;77(Suppl. 3):950-6. https://doi.org/10.1007/s12262-014-1078-6
84. Hameed B, Mehta N, Sapisochin G, Roberts JP, Yao FY. Alpha-fetoprotein level >1,000 ng/mL as an exclusion criterion for liver transplantation in patients with hepatocellular carcinoma meeting the Milan criteria. Liver Transpl. 2014;20(8):945-51. https://doi.org/10.1002/lt.23904
85. Han J, Fan YC, Wang K. Radiofrequency ablation versus microwave ablation for early stage hepatocellular carcinoma: A PRISMA-compliant systematic review and meta-analysis. Medicine. 2020;99(43):e22703. https://doi.org/10.1097/MD.0000000000022703
86. Hart A, Engels EA. Balancing uncertain risks in candidates for solid organ transplantation with a history of malignancy: Who is safe to transplant? Am J Transplant. 2021;21(2):447-8. https://doi.org/10.1111/ajt.16366
87. Hasskarl J. Everolimus. Recent Results Cancer Res. 2018;211:101-23. https://doi.org/10.1007/978-3-319-91442-8_8
88. Hayashi S, Baba Y, Ueno K, Nakajo M, Kubo F, Ueno S, et al. Acceleration of primary liver tumor growth rate in embolized hepatic lobe after portal vein embolization. Acta Radiol. 2007;48(7):721-7. https://doi.org/10.1080/02841850701424514
89. Heimbach JK, Kulik LM, Finn RS, Sirlin CB, Abecassis MM, Roberts LR, et al. AASLD guidelines for the treatment of hepatocellular carcinoma. Hepatology. 2018;67(1):358-80. https://doi.org/10.1002/hep.29086
90. Hester CA, Yopp AC. Surgical therapies in hepatocellular carcinoma. In: Hoshida Y, editor. Hepatocellular carcinoma: translational precision medicine approaches. Cham: Humana Press; 2019. chapter 8.
91. Hsu KY, Chau GY, Lui WY, Tsay SH, King KL, Wu CW. Predicting morbidity and mortality after hepatic resection in patients with hepatocellular carcinoma: the role of Model for End-Stage Liver Disease score. World J Surg. 2009;33(11):2412-9. https://doi.org/10.1007/s00268-009-0202-4
92. Imamura H, Sano K, Sugawara Y, Kokudo N, Makuuchi M. Assessment of hepatic reserve for indication of hepatic resection: decision tree incorporating indocyanine green test. J Hepatobiliary Pancreat Surg. 2005;12(1):16-22. https://doi.org/10.1007/s00534-004-0965-9
93. Iñarrairaegui M, Thurston KG, Bilbao JI, D'Avola D, Rodriguez M, Arbizu J, et al. Radioembolization with use of yttrium-90 resin microspheres in patients with hepatocellular carcinoma and portal vein thrombosis. J Vasc Interv Radiol. 2010;21(8):1205-12. https://doi.org/10.1016/j.jvir.2010.04.012
94. Ishizawa T, Hasegawa K, Aoki T, Takahashi M, Inoue Y, Sano K, et al. Neither multiple tumors nor portal hypertension are surgical contraindications for hepatocellular carcinoma. Gastroenterology. 2008;134(7):1908-16. https://doi.org/10.1053/j.gastro.2008.02.091
95. Kaido T, Ogawa K, Mori A, Fujimoto Y, Ito T, Tomiyama K, et al. Usefulness of the Kyoto criteria as expanded selection criteria for liver transplantation for hepatocellular carcinoma. Surgery. 2013;154(5):1053-60. https://doi.org/10.1016/j.surg.2013.04.056
96. Kaneko H, Tsuchiya M, Otsuka Y, Yajima S, Minagawa T, Watanabe M, et al. Laparoscopic hepatectomy for hepatocellular carcinoma in cirrhotic patients. J Hepatobiliary Pancreat Surg. 2009;16(4):433-8. https://doi.org/10.1007/s00534-009-0123-5
97. Kaseb AO, Hasanov E, Cao HST, Xiao L, Vauthey JN, Lee SS, et al. Perioperative nivolumab monotherapy versus nivolumab plus ipilimumab in resectable hepatocellular carcinoma: a randomised, open-label, phase 2 trial. Lancet Gastroenterol Hepatol. 2022;7(3):208-18. https://doi.org/10.1016/S2468-1253(21)00427-1
98. Kawaguchi Y, Hasegawa K, Kashiwabara K, Okamura Y, Kurosaki M, Kudo M, et al. Surgery versus ablation for hepatocellular carcinoma: a randomized controlled trial (SURF-RCT Trial) and a nonrandomized prospective observational trial (SURF-Cohort Trial). J Clin Oncol. 2025;43(23):2628-38. https://doi.org/10.1200/JCO-24-02030
99. Kawaguchi Y, Lillemoe HA, Vauthey JN. Surgical resection: old dog, any new tricks? Clin Liver Dis. 2020;24(4):637-55. https://doi.org/10.1016/j.cld.2020.07.004
100. Kawahara T, Asthana S, Kneteman NM. m-TOR inhibitors: what role in liver transplantation? J Hepatol. 2011;55(6):1441-51. https://doi.org/10.1016/j.jhep.2011.06.015
101. Kawamura Y, Akuta N, Shindoh J, Matsumura M, Okubo S, Tominaga L, et al. Newly established borderline resectable 1 (BR1) category is one of the favorable candidates for selecting the use of multidisciplinary combination therapy in patients with advanced hepatocellular carcinoma treated with systemic therapy. Hepatol Res. 2025;55(2):275-82. https://doi.org/10.1111/hepr.14114
102. Kim D, Kim JS. Current perspectives on radiotherapy in hepatocellular carcinoma management: a comprehensive review. J Liver Cancer. 2024;24(1):33-46. https://doi.org/10.17998/jlc.2024.02.26
103. Kim JH, Won HJ, Shin YM, Kim SH, Yoon HK, Sung KB, et al. Medium-sized (3.1-5.0 cm) hepatocellular carcinoma: transarterial chemoembolization plus radiofrequency ablation versus radiofrequency ablation alone. Ann Surg Oncol. 2011;18(6):1624-9. https://doi.org/10.1245/s10434-011-1673-8
104. Knox J, Cheng A, Cleary S, Galle P, Kokudo N, Lencioni R, et al. A phase 3 study of durvalumab with or without bevacizumab as adjuvant therapy in patients with hepatocellular carcinoma at high risk of recurrence after curative hepatic resection or ablation: EMERALD-2. Annals of Oncology. 2019;30(Suppl. 4):iv59-iv60. https://doi.org/10.1093/annonc/mdz155.216
105. Koh JH, Tan DJH, Ong Y, Lim WH, Ng CH, Tay PWL, et al. Liver resection versus liver transplantation for hepatocellular carcinoma within Milan criteria: a meta-analysis of 18,421 patients. Hepatobiliary Surg Nutr. 2022;11(1):78-93. https://doi.org/10.21037/hbsn-21-350
106. Kokabi N, Camacho JC, Xing M, El-Rayes BF, Spivey JR, Knechtle SJ, et al. Open-label prospective study of the safety and efficacy of glass-based yttrium 90 radioembolization for infiltrative hepatocellular carcinoma with portal vein thrombosis. Cancer. 2015;121(13):2164-74. https://doi.org/10.1002/cncr.29275

107. Kokudo N, Takemura N, Hasegawa K, Takayama T, Kubo S, Shimada M, et al. Clinical practice guidelines for hepatocellular carcinoma: The Japan Society of Hepatology 2017 (4th JSH-HCC guidelines) 2019 update. Hepatol Res. 2019;49(10):1109-13. https://doi.org/10.1111/hepr.13411
108. Kokudo T, Hasegawa K, Matsuyama Y, Takayama T, Izumi N, Kadoya M, et al. Survival benefit of liver resection for hepatocellular carcinoma associated with portal vein invasion. J Hepatol. 2016;65(5):938-43. https://doi.org/10.1016/j.jhep.2016.05.044
109. Kokudo T, Kokudo N. Evolving indications for liver transplantation for hepatocellular carcinoma following the Milan Criteria. Cancers. 2025;17(3):507. https://doi.org/10.3390/cancers17030507
110. Konerman MA, Fritze D, Weinberg RL, Sonnenday CJ, Sharma P. Incidence of and risk assessment for adverse cardiovascular outcomes after liver transplantation: a systematic review. Transplantation. 2017;101(7):1645-57. https://doi.org/10.1097/TP.0000000000001710
111. Kudo M, Imanaka K, Chida N, Nakachi K, Tak WY, Takayama T, et al. Phase III study of sorafenib after transarterial chemoembolisation in Japanese and Korean patients with unresectable hepatocellular carcinoma. Eur J Cancer. 2011;47(14):2117-27. https://doi.org/10.1016/j.ejca.2011.05.007
112. Kudo M, Kawamura Y, Hasegawa K, Tateishi R, Kariyama K, Shiina S, et al. Management of hepatocellular carcinoma in Japan: JSH Consensus Statements and Recommendations 2021 Update. Liver Cancer. 2021;10(3):181-223. https://doi.org/10.1159/000514174
113. Kudo M, Ren Z, Guo Y, Han G, Lin H, Zheng J, et al. Transarterial chemoembolisation combined with lenvatinib plus pembrolizumab versus dual placebo for unresectable, non-metastatic hepatocellular carcinoma (LEAP-012): a multicentre, randomised, double-blind, phase 3 study. Lancet. 2025;405(10474):203-15. https://doi.org/10.1016/S0140-6736(24)02575-3
114. Kulik LM, Carr BI, Mulcahy MF, Lewandowski RJ, Atassi B, Ryu RK, et al. Safety and efficacy of 90Y radiotherapy for hepatocellular carcinoma with and without portal vein thrombosis. Hepatology. 2008;47(1):71-81. https://doi.org/10.1002/hep.21980
115. Kwong A, Kim WR, Lake JR, Smith JM, Schladt DP, Skeans MA, et al. OPTN/SRTR 2018 annual data report: liver. Am J Transplant. 2020;20(Suppl. 1):193-299. https://doi.org/10.1111/ajt.15674
116. Lai Q, Sapisochin G, Gorgen A, Vitale A, Halazun KJ, Iesari S, et al. Evaluation of the intention-to-treat benefit of living donation in patients with hepatocellular carcinoma awaiting a liver transplant. JAMA Surg. 2021;156(9):e213112. https://doi.org/10.1001/jamasurg.2021.3112
117. Lammer J, Malagari K, Vogl T, Pilleul F, Denys A, Watkinson A, et al. Prospective randomized study of doxorubicin-eluting-bead embolization in the treatment of hepatocellular carcinoma: results of the PRECISION V study. Cardiovasc Intervent Radiol. 2010;33(1):41-52. https://doi.org/10.1007/s00270-009-9711-7
118. Lee DH, Kim D, Park YH, Yoon J, Kim JS. Long-term surgical outcomes in patients with hepatocellular carcinoma undergoing laparoscopic vs. open liver resection: A retrospective and propensity score-matched study. Asian J Surg. 2021;44(1):206-12. https://doi.org/10.1016/j.asjsur.2020.05.028
119. Lee J, Shin IS, Yoon WS, Koom WS, Rim CH. Comparisons between radiofrequency ablation and stereotactic body radiotherapy for liver malignancies: Meta-analyses and a systematic review. Radiother Oncol. 2020;145:63-70. https://doi.org/10.1016/j.radonc.2019.12.004
120. Lee JH, Cho Y, Kim HY, Cho EJ, Lee DH, Yu SJ, et al. Serum tumor markers provide refined prognostication in selecting liver transplantation candidate for hepatocellular carcinoma patients beyond the Milan Criteria. Ann Surg. 2016;263(5):842-50. https://doi.org/10.1097/SLA.0000000000001578
121. Lee SD, Lee B, Kim SH, Joo J, Kim SK, Kim YK, et al. Proposal of new expanded selection criteria using total tumor size and (18)F-fluorodeoxyglucose - positron emission tomography/computed tomography for living donor liver transplantation in patients with hepatocellular carcinoma: The National Cancer Center Korea criteria. World J Transplant. 2016;6(2):411-22. https://doi.org/10.5500/wjt.v6.i2.411
122. Lencioni R, Crocetti L, Narayanan G. Irreversible electroporation in the treatment of hepatocellular carcinoma. Tech Vasc Interv Radiol. 2015;18(3):135-9. https://doi.org/10.1053/j.tvir.2015.06.003
123. Lencioni R, Baere T, Martin RC, Nutting CW, Narayanan G. Image-guided ablation of malignant liver tumors: recommendations for clinical validation of novel thermal and non-thermal technologies: a Western perspective. Liver Cancer. 2015;4(4):208-14. https://doi.org/10.1159/000367747
124. Lencioni R, Llovet JM, Han G, Tak WY, Yang J, Guglielmi A, et al. Sorafenib or placebo plus TACE with doxorubicin-eluting beads for intermediate stage HCC: The SPACE trial. J Hepatol. 2016;64(5):1090-8. https://doi.org/10.1016/j.jhep.2016.01.012
125. Li C, Wang MD, Lu L, Wu H, Yu JJ, Zhang WG, et al. Preoperative transcatheter arterial chemoembolization for surgical resection of huge hepatocellular carcinoma (≥10 cm): a multicenter propensity matching analysis. Hepatol Int. 2019;13(6):736-47. https://doi.org/10.1007/s12072-019-09981-0
126. Liang L, Li C, Diao YK, Jia HD, Xing H, Pawlik TM, et al. Survival benefits from adjuvant transcatheter arterial chemoembolization in patients undergoing liver resection for hepatocellular carcinoma: a systematic review and meta-analysis. Ther Adv Gastroenterol. 2020;13:1756284820977693. https://doi.org/10.1177/1756284820977693
127. Liang L, Xing H, Zhang H, Zhong J, Li C, Lau WY, et al. Surgical resection versus transarterial chemoembolization for BCLC intermediate stage hepatocellular carcinoma: a systematic review and meta-analysis. HPB. 2018;20(2):110-9. https://doi.org/10.1016/j.hpb.2017.10.004
128. Lim KC, Chow PK, Allen JC, Chia GS, Lim M, Cheow PC, et al. Microvascular invasion is a better predictor of tumor recurrence and overall survival following surgical resection for hepatocellular carcinoma compared to the Milan criteria. Ann Surg. 2011;254(1):108-13. https://doi.org/10.1097/SLA.0b013e31821ad884
129. Limkemann AJP, Abreu P, Sapisochin G. How far can we go with hepatocellular carcinoma in living donor liver transplantation? Curr Opin Organ Transplant. 2019;24(5):644-50. https://doi.org/10.1097/MOT.0000000000000692

130. Liu H, Hu FJ, Li H, Lan T, Wu H. Anatomical vs non-anatomical liver resection for solitary hepatocellular carcinoma: A systematic review and meta-analysis. World J Gastrointest Oncol. 2021;13(11):1833-46. https://doi.org/10.4251/wjgo.v13.i11.1833
131. Livraghi T, Giorgio A, Marin G, Salmi A, Sio I, Bolondi L, et al. Hepatocellular carcinoma and cirrhosis in 746 patients: long-term results of percutaneous ethanol injection. Radiology. 1995;197(1):101-8. https://doi.org/10.1148/radiology.197.1.7568806
132. Livraghi T, Goldberg SN, Lazzaroni S, Meloni F, Solbiati L, Gazelle GS. Small hepatocellular carcinoma: treatment with radio-frequency ablation versus ethanol injection. Radiology. 1999;210(3):655-61. https://doi.org/10.1148/radiology.210.3.r99fe40655
133. Livraghi T. Percutaneous ethanol injection in the treatment of hepatocellular carcinoma in cirrhosis. Hepatogastroenterology. 2001;48(37):20-4.
134. Llovet JM, Brú C, Bruix J. Prognosis of hepatocellular carcinoma: the BCLC staging classification. Semin Liver Dis. 1999;19(3):329-38. https://doi.org/10.1055/s-2007-1007122
135. Llovet JM, Schwartz M, Mazzaferro V. Resection and liver transplantation for hepatocellular carcinoma. Semin Liver Dis. 2005;25(2):181-200. https://doi.org/10.1055/s-2005-871198
136. Lobo L, Yakoub D, Picado O, Ripat C, Pendola F, Sharma R, et al. Unresectable hepatocellular carcinoma: radioembolization versus chemoembolization: a systematic review and meta-analysis. Cardiovasc Intervent Radiol. 2016;39(11):1580-8. https://doi.org/10.1007/s00270-016-1426-y. Erratum in: Cardiovasc Intervent Radiol. 2017;40(9):1487. https://doi.org/10.1007/s00270-017-1693-2
137. Loveday BPT, Jaberi A, Moulton CA, Wei AC, Gallinger S, Beecroft R, et al. Effect of portal vein embolization on treatment plan prior to major hepatectomy for hepatocellular carcinoma. HPB. 2019;21(8):1072-8. https://doi.org/10.1016/j.hpb.2018.12.009
138. Maccali C, Chagas AL, Boin I, Quiñonez E, Marciano S, Vilatobá M, et al. Recurrence of hepatocellular carcinoma after liver transplantation: Prognostic and predictive factors of survival in a Latin American cohort. Liver Int. 2021;41(4):851-62. https://doi.org/10.1111/liv.14736
139. Majno P, Mazzaferro V. Living donor liver transplantation for hepatocellular carcinoma exceeding conventional criteria: questions, answers and demands for a common language. Liver Transpl. 2006;12(6):896-8. https://doi.org/10.1002/lt.20808
140. Makary MS, Khandpur U, Cloyd JM, Mumtaz K, Dowell JD. Locoregional therapy approaches for hepatocellular carcinoma: recent advances and management strategies. Cancers. 2020;12(7):1914. https://doi.org/10.3390/cancers12071914
141. Manzia TM, Antonelli B, Carraro A, Conte G, Guglielmo N, Lauterio A, et al. Immunosuppression in adult liver transplant recipients: a 2024 update from the Italian Liver Transplant Working Group. Hepatol Int. 2024;18(5):1416-30. https://doi.org/10.1007/s12072-024-10703-4
142. Manzia TM, Lai Q, Iesari S, Perera MTPR, Komuta M, Carvalheiro A, et al. Impact of remnant vital tissue after locoregional treatment and liver transplant in hepatocellular cancer patients, a multicentre cohort study. Transpl Int. 2018;31(9):988-98. https://doi.org/10.1111/tri.13153
143. Marrero JA, Kulik LM, Sirlin CB, Zhu AX, Finn RS, Abecassis MM, et al. Diagnosis, staging, and management of hepatocellular carcinoma: 2018 practice guidance by the American Association for the Study of Liver Diseases. Hepatology. 2018;68(2):723-50. https://doi.org/10.1002/hep.29913
144. Marron TU, Fiel MI, Hamon P, Fiaschi N, Kim E, Ward SC, et al. Neoadjuvant cemiplimab for resectable hepatocellular carcinoma: a single-arm, open-label, phase 2 trial. Lancet Gastroenterol Hepatol. 2022;7(3):219-29. https://doi.org/10.1016/s2468-1253(21)00385-x
145. Martin P, DiMartini A, Feng S, Brown R Jr, Fallon M. Evaluation for liver transplantation in adults: 2013 practice guideline by the American Association for the Study of Liver Diseases and the American Society of Transplantation. Hepatology. 2014;59(3):1144-65. https://doi.org/10.1002/hep.26972
146. May BJ, Madoff DC. Portal vein embolization: rationale, technique, and current application. Semin Intervent Radiol. 2012;29(2):81-9. https://doi.org/10.1055/s-0032-1312568
147. Mazzaferro V, Bhoori S, Sposito C, Bongini M, Langer M, Miceli R, et al. Milan criteria in liver transplantation for hepatocellular carcinoma: an evidence-based analysis of 15 years of experience. Liver Transpl. 2011;17(Suppl. 2):S44-57. https://doi.org/10.1002/lt.22365
148. Mazzaferro V, Llovet JM, Miceli R, Bhoori S, Schiavo M, Mariani L, et al. Predicting survival after liver transplantation in patients with hepatocellular carcinoma beyond the Milan criteria: a retrospective, exploratory analysis. Lancet Oncol. 2009;10(1):35-43. https://doi.org/10.1016/S1470-2045(08)70284-5
149. Mazzaferro V, Regalia E, Doci R, Andreola S, Pulvirenti A, Bozzetti F, et al. Liver transplantation for the treatment of small hepatocellular carcinomas in patients with cirrhosis. N Engl J Med. 1996;334(11):693-700. https://doi.org/10.1056/NEJM199603143341104
150. Mazzaferro V, Roayaie S, Poon R, Majno PE. Dissecting EASL/AASLD recommendations with a more careful knife: a comment on "surgical misinterpretation" of the BCLC Staging System. Ann Surg. 2015;262(1):e17-8. https://doi.org/10.1097/SLA.0000000000000398
151. Mazzaferro V, Sposito C, Zhou J, Pinna AD, Carlis L, Fan J, et al. Metroticket 2.0 model for analysis of competing risks of death after liver transplantation for hepatocellular carcinoma. Gastroenterology. 2018;154(1):128-39. https://doi.org/10.1053/j.gastro.2017.09.025
152. Mazzaferro V. Squaring the circle of selection and allocation in liver transplantation for HCC: An adaptive approach. Hepatology. 2016;63(5):1707-17. https://doi.org/10.1002/hep.28420
153. Mehta N, Bhangui P, Yao FY, Mazzaferro V, Toso C, Akamatsu N, et al. Liver transplantation for hepatocellular carcinoma. Working Group Report from the ILTS Transplant Oncology Consensus Conference. Transplantation. 2020;104(6):1136-42. https://doi.org/10.1097/TP.0000000000003174
154. Mehta N, Dodge JL, Roberts JP, Hirose R, Yao FY. Alpha-fetoprotein decrease from >1,000 to <500 ng/mL in patients with hepatocellular carcinoma leads to improved

posttransplant outcomes. Hepatology. 2019;69(3):1193-205. https://doi.org/10.1002/hep.30413
155. Meyer J, Balaphas A, Combescure C, Morel P, Gonelle-Gispert C, Bühler L. Systematic review and meta-analysis of thrombocytopenia as a predictor of post-hepatectomy liver failure. HPB. 2019;21(11):1419-26. https://doi.org/10.1016/j.hpb.2019.01.016
156. Meyer T, Fox R, Ma YT, Ross PJ, James MW, Sturgess R, et al. Sorafenib in combination with transarterial chemoembolisation in patients with unresectable hepatocellular carcinoma (TACE 2): a randomised placebo-controlled, double-blind, phase 3 trial. Lancet Gastroenterol Hepatol. 2017;2(8):565-75. https://doi.org/10.1016/S2468-1253(17)30156-5
157. Mohan BP, Iriana S, Khan SR, Yarra P, Ponnada S, Gallegos-Orozco JF. Outcomes of liver transplantation in patients 70 years or older: a systematic review and meta-analysis. Ann Hepatol. 2022;27(6):100741. https://doi.org/10.1016/j.aohep.2022.100741
158. Morise Z, Wakabayashi G. First quarter century of laparoscopic liver resection. World J Gastroenterol. 2017;23(20):3581-8. https://doi.org/10.3748/wjg.v23.i20.3581
159. Morris PD, Laurence JM, Yeo D, Crawford M, Strasser SI, McCaughan GW, et al. Can response to locoregional therapy help predict longterm survival after liver transplantation for hepatocellular carcinoma? A systematic review. Liver Transpl. 2017;23(3):375-85. https://doi.org/10.1002/lt.24689
160. Murtha-Lemekhova A, Fuchs J, Hoffmann K. Innovation for the Sake of Innovation? How does robotic hepatectomy compare to laparoscopic or open resection for HCC: A systematic review and meta-analysis. Cancers. 2022;14(14):3359. https://doi.org/10.3390/cancers14143359
161. Narayanan G, Froud T, Suthar R, Barbery K. Irreversible electroporation of hepatic malignancy. Semin Intervent Radiol. 2013;30(1):67-73. https://doi.org/10.1055/s-0033-1333655
162. Ng AC. Stick to Milan: Infeasibility of the Brazil-Milan Criteria in recommending patients with hepatocellular carcinoma for liver transplantation. Ann Hepatol. 2021;25:100537. https://doi.org/10.1016/j.aohep.2021.100537
163. Orlando A, Leandro G, Olivo M, Andriulli A, Cottone M. Radiofrequency thermal ablation vs. percutaneous ethanol injection for small hepatocellular carcinoma in cirrhosis: meta-analysis of randomized controlled trials. Am J Gastroenterol. 2009;104(2):514-24. https://doi.org/10.1038/ajg.2008.80
164. Özdemir F, Baskiran A. The importance of AFP in liver transplantation for HCC. J Gastrointest Cancer. 2020;51(4):1127-32. https://doi.org/10.1007/s12029-020-00486-w
165. Pang Q, Qu K, Zhang JY, Song SD, Liu SS, Tai MH, et al. The prognostic value of platelet count in patients with hepatocellular carcinoma: a systematic review and meta-analysis. Medicine. 2015;94(37):e1431. https://doi.org/10.1097/MD.0000000000001431
166. Pang Q, Zhang JY, Xu XS, Song SD, Qu K, Chen W, et al. Significance of platelet count and platelet-based models for hepatocellular carcinoma recurrence. World J Gastroenterol. 2015;21(18):5607-21. https://doi.org/10.3748/wjg.v21.i18.5607
167. Park GC, Lee SG, Yoon YI, Sung KB, Ko GY, Gwon DI, et al. Sequential transcatheter arterial chemoembolization and portal vein embolization before right hemihepatectomy in patients with hepatocellular carcinoma. Hepatobiliary Pancreat Dis Int. 2020;19(3):244-51. https://doi.org/10.1016/j.hbpd.2020.04.008
168. Park JW, Chen M, Colombo M, Roberts LR, Schwartz M, Chen PJ, et al. Global patterns of hepatocellular carcinoma management from diagnosis to death: the BRIDGE Study. Liver Int. 2015;35(9):2155-66. https://doi.org/10.1111/liv.12818
169. Pascale MM, Marandola C, Frongillo F, Nure E, Agnes S. Locoregional and surgical treatment of single-nodule hepatocellular carcinoma recurrence after liver transplantation: a systematic review and a meta-analysis. Cancers. 2025;17(9):1501. https://doi.org/10.3390/cancers17091501
170. Patel KR, Menon H, Patel RR, Huang EP, Verma V, Escorcia FE. Locoregional therapies for hepatocellular carcinoma: a systematic review and meta-analysis. JAMA Netw Open. 2024;7(11):e2447995. https://doi.org/10.1001/jamanetworkopen.2024.47995
171. Pavel MC, Fuster J. Expansion of the hepatocellular carcinoma Milan criteria in liver transplantation: Future directions. World J Gastroenterol. 2018;24(32):3626-36. https://doi.org/10.3748/wjg.v24.i32.3626
172. Pelizzaro F, Penzo B, Peserico G, Imondi A, Sartori A, Vitale A, et al. Monofocal hepatocellular carcinoma: How much does size matter? Liver Int. 2021;41(2):396-407. https://doi.org/10.1111/liv.14718
173. Peng Z, Fan W, Zhu B, Wang G, Sun J, Xiao C, et al. Lenvatinib combined with transarterial chemoembolization as first-line treatment for advanced hepatocellular carcinoma: a phase III, randomized clinical trial (LAUNCH). J Clin Oncol. 2023;41(1):117-27. https://doi.org/10.1200/JCO.22.00392
174. Peng ZW, Lin XJ, Zhang YJ, Liang HH, Guo RP, Shi M, et al. Radiofrequency ablation versus hepatic resection for the treatment of hepatocellular carcinomas 2 cm or smaller: a retrospective comparative study. Radiology. 2012;262(3):1022-33. https://doi.org/10.1148/radiol.11110817
175. Peng ZW, Zhang YJ, Liang HH, Lin XJ, Guo RP, Chen MS. Recurrent hepatocellular carcinoma treated with sequential transcatheter arterial chemoembolization and RF ablation versus RF ablation alone: a prospective randomized trial. Radiology. 2012;262(2):689-700. https://doi.org/10.1148/radiol.11110637
176. Pinna AD, Yang T, Mazzaferro V, Carlis L, Zhou J, Roayaie S, et al. Liver transplantation and hepatic resection can achieve cure for hepatocellular carcinoma. Ann Surg. 2018;268(5):868-75. https://doi.org/10.1097/SLA.0000000000002889
177. Qadan M, Fong ZV, Delman AM, Gabr A, Salem R, Shah SA. Review of use of Y90 as a bridge to liver resection and transplantation in hepatocellular carcinoma. J Gastrointest Surg. 2021;25(10):2690-9. https://doi.org/10.1007/s11605-021-05095-x
178. Qadan M, Kothary N, Sangro B, Palta M. The treatment of hepatocellular carcinoma with portal vein tumor thrombosis. Am Soc Clin Oncol Educ Book. 2020;40:174-85. https://doi.org/10.1200/EDBK_280811

179. Qiu G, Xie K, Jin Z, Jiang C, Liu H, Wan H, et al. The multidisciplinary management of hepatocellular carcinoma with portal vein tumor thrombus. Biosci Trends. 2021;15(3):148-54. https://doi.org/10.5582/bst.2021.01173
180. Quireze Junior C, Coelho FF, Lima AS, Marques HP, Palavecino M, Pawlik T, et al. Complications after hepatectomy. Arq Bras Cir Dig. 2025;37:e1856. https://doi.org/10.1590/0102-6720202400062e1856
181. Raoul JL, Forner A, Bolondi L, Cheung TT, Kloeckner R, Baere T. Updated use of TACE for hepatocellular carcinoma treatment: How and when to use it based on clinical evidence. Cancer Treat Rev. 2019;72:28-36. https://doi.org/10.1016/j.ctrv.2018.11.002
182. Refaat R, Basha MAA, Hassan MS, Hussein RS, El Sammak AA, El Sammak DAEA, et al. Efficacy of contrast-enhanced FDG PET/CT in patients awaiting liver transplantation with rising alpha-fetoprotein after bridge therapy of hepatocellular carcinoma. Eur Radiol. 2018;28(12):5356-67. https://doi.org/10.1007/s00330-018-5425-z
183. Reig M, Forner A, Rimola J, Ferrer-Fàbrega J, Burrel M, Garcia-Criado Á, et al. BCLC strategy for prognosis prediction and treatment recommendation: The 2022 update. J Hepatol. 2022;76(3):681-93. https://doi.org/10.1016/j.jhep.2021.11.018
184. Reig M, Sanduzzi-Zamparelli M, Forner A, Rimola J, Ferrer-Fàbrega J, Burrel M, et al. BCLC strategy for prognosis prediction and treatment recommendations: The 2026 update. J Hepatol. 2026;84(3):631-54. https://doi.org/10.1016/j.jhep.2025.10.020
185. Rim CH, Kim HJ, Seong J. Clinical feasibility and efficacy of stereotactic body radiotherapy for hepatocellular carcinoma: A systematic review and meta-analysis of observational studies. Radiother Oncol. 2019;131:135-44. https://doi.org/10.1016/j.radonc.2018.12.005
186. Rodríguez-Perálvarez M, Tsochatzis E, Naveas MC, Pieri G, García-Caparrós C, O'Beirne J, et al. Reduced exposure to calcineurin inhibitors early after liver transplantation prevents recurrence of hepatocellular carcinoma. J Hepatol. 2013;59(6):1193-9. https://doi.org/10.1016/j.jhep.2013.07.012
187. Rodríguez S, Fleck AM Jr., Mucenic M, Marroni C, Brandão A. Hepatocellular carcinoma patients are advantaged in the current Brazilian liver transplant allocation system. A competing risk analysis. Arq Gastroenterol. 2020;57(1):19-23. https://doi.org/10.1590/S0004-2803.202000000-05
188. Romagnoli R, Mazzaferro V, Bruix J. Surgical resection for hepatocellular carcinoma: Moving from what can be done to what is worth doing. Hepatology. 2015;62(2):340-2. https://doi.org/10.1002/hep.27831
189. Ruch B, Wagler J, Kumm K, Zhang C, Katariya NN, Garcia-Saenz-de-Sicilia M, et al. Hepatocellular carcinoma, alpha fetoprotein, and liver allocation for transplantation: past, present and future. Curr Oncol. 2022;29(10):7537-51. https://doi.org/10.3390/curroncol29100593
190. Sá GP, Vicentine FP, Salzedas-Netto AA, Matos CA, Romero LR, Tejada DF, et al. Liver transplantation for carcinoma hepatocellular in São Paulo: 414 cases by the Milan/Brazil criteria. Arq Bras Cir Dig. 2016;29(4):240-5. https://doi.org/10.1590/0102-6720201600040007
191. Salcedo M, Vinaixa C, Javle M, Trapero-Marugán M, Bustamante J, Line PD. Evaluation and management of liver transplant candidates with prior nonhepatic cancer: guidelines from the ILTS/SETH Consensus Conference. Transplantation. 2022;106(1):e3-e11. https://doi.org/10.1097/TP.0000000000003997
192. Salem R, Gordon AC, Mouli S, Hickey R, Kallini J, Gabr A, et al. Y90 radioembolization significantly prolongs time to progression compared with chemoembolization in patients with hepatocellular carcinoma. Gastroenterology. 2016;151(6):1155-63.e2. https://doi.org/10.1053/j.gastro.2016.08.029
193. Salem R, Johnson GE, Kim E, Riaz A, Bishay V, Boucher E, et al. Yttrium-90 radioembolization for the treatment of solitary, unresectable HCC: The LEGACY Study. Hepatology. 2021;74(5):2342-52. https://doi.org/10.1002/hep.31819
194. Sangro B, Kudo M, Erinjeri JP, Qin S, Ren Z, Chan SL, et al. Durvalumab with or without bevacizumab with transarterial chemoembolisation in hepatocellular carcinoma (EMERALD-1): a multiregional, randomised, double-blind, placebo-controlled, phase 3 study. Lancet. 2025;405(10474):216-32. https://doi.org/10.1016/S0140-6736(24)02551-0
195. Sapisochin G, Goldaracena N, Astete S, Laurence JM, Davidson D, Rafael E, et al. Benefit of treating hepatocellular carcinoma recurrence after liver transplantation and analysis of prognostic factors for survival in a large Euro-American series. Ann Surg Oncol. 2015;22(7):2286-94. https://doi.org/10.1245/s10434-014-4273-6
196. Sapisochin G, Goldaracena N, Laurence JM, Dib M, Barbas A, Ghanekar A, et al. The extended Toronto criteria for liver transplantation in patients with hepatocellular carcinoma: A prospective validation study. Hepatology. 2016;64(6):2077-88. https://doi.org/10.1002/hep.28643
197. Schrecker C, Waidmann O, El Youzouri H, Trojan J, Schnitzbauer AA, Bechstein WO, et al. Low platelet count predicts reduced survival in potentially resectable hepatocellular carcinoma. Curr Oncol. 2022;29(3):1475-87. https://doi.org/10.3390/curroncol29030124
198. Shen A, Zhang H, Tang C, Chen Y, Wang Y, Zhang C, et al. Systematic review of radiofrequency ablation versus percutaneous ethanol injection for small hepatocellular carcinoma up to 3 cm. J Gastroenterol Hepatol. 2013;28(5):793-800. https://doi.org/10.1111/jgh.12162
199. Shi J, Lai EC, Li N, Guo WX, Xue J, Lau WY, et al. A new classification for hepatocellular carcinoma with portal vein tumor thrombus. J Hepatobiliary Pancreat Sci. 2011;18(1):74-80. https://doi.org/10.1007/s00534-010-0314-0
200. Shibata T, Iimuro Y, Yamamoto Y, Maetani Y, Ametani F, Itoh K, et al. Small hepatocellular carcinoma: comparison of radio-frequency ablation and percutaneous microwave coagulation therapy. Radiology. 2002;223(2):331-7. https://doi.org/10.1148/radiol.2232010775
201. Shindoh J, Makuuchi M, Matsuyama Y, Mise Y, Arita J, Sakamoto Y, et al. Complete removal of the tumor-bearing portal territory decreases local tumor recurrence and improves disease-specific survival of patients with hepatocellular carcinoma. J Hepatol. 2016;64(3):594-600. https://doi.org/10.1016/j.jhep.2015.10.015
202. Sieghart W, Hucke F, Peck-Radosavljevic M. Transarterial chemoembolization: modalities, indication, and patient selection. J Hepatol. 2015;62(5):1187-95. https://doi.org/10.1016/j.jhep.2015.02.010

203. Silk T, Silk M, Wu J. Up to seven criteria in selection of systemic therapy for hepatocellular carcinoma. World J Gastroenterol. 2022;28(23):2561-8. https://doi.org/10.3748/wjg.v28.i23.2561
204. Sotiropoulos GC, Prodromidou A, Kostakis ID, Machairas N. Meta-analysis of laparoscopic vs open liver resection for hepatocellular carcinoma. Updates Surg. 2017;69(3):291-311. https://doi.org/10.1007/s13304-017-0421-4
205. Su GL, Altayar O, O'Shea R, Shah R, Estfan B, Wenzell C, et al. AGA clinical practice guideline on systemic therapy for hepatocellular carcinoma. Gastroenterology. 2022;162(3):920-34. https://doi.org/10.1053/j.gastro.2021.12.276
206. Sugimoto K, Imajo K, Kuroda H, Murohisa G, Shiozawa K, Sakamaki K, et al. Microwave ablation *vs.* single-needle radiofrequency ablation for the treatment of HCC up to 4 cm: A randomized-controlled trial. JHEP Rep. 2025;7(1):101269. https://doi.org/10.1016/j.jhepr.2024.101269
207. Takayama T, Hasegawa K, Izumi N, Kudo M, Shimada M, Yamanaka N, et al. Surgery versus radiofrequency ablation for small hepatocellular carcinoma: a randomized controlled trial (SURF Trial). Liver Cancer. 2022;11(3):209-18. https://doi.org/10.1159/000521665
208. Takayasu K, Arii S, Kudo M, Ichida T, Matsui O, Izumi N, et al. Superselective transarterial chemoembolization for hepatocellular carcinoma. Validation of treatment algorithm proposed by Japanese guidelines. J Hepatol. 2012;56(4):886-92. https://doi.org/10.1016/j.jhep.2011.10.021
209. Teh SH, Christein J, Donohue J, Que F, Kendrick M, Farnell M, et al. Hepatic resection of hepatocellular carcinoma in patients with cirrhosis: Model of End-Stage Liver Disease (MELD) score predicts perioperative mortality. J Gastrointest Surg. 2005;9(9):1207-15. https://doi.org/10.1016/j.gassur.2005.09.008
210. Terasawa M, Allard MA, Golse N, Cunha AS, Cherqui D, Adam R, et al. Sequential transcatheter arterial chemoembolization and portal vein embolization versus portal vein embolization alone before major hepatectomy for patients with large hepatocellular carcinoma: An intent-to-treat analysis. Surgery. 2020;167(2):425-31. https://doi.org/10.1016/j.surg.2019.09.023
211. Torzilli G, Belghiti J, Kokudo N, Takayama T, Capussotti L, Nuzzo G, et al. A snapshot of the effective indications and results of surgery for hepatocellular carcinoma in tertiary referral centers: is it adherent to the EASL/AASLD recommendations?: an observational study of the HCC East-West study group. Ann Surg. 2013;257(5):929-37. https://doi.org/10.1097/SLA.0b013e31828329b8
212. Troisi RI, Berardi G, Morise Z, Cipriani F, Ariizumi S, Sposito C, et al. Laparoscopic and open liver resection for hepatocellular carcinoma with Child-Pugh B cirrhosis: multicentre propensity score-matched study. Br J Surg. 2021;108(2):196-204. https://doi.org/10.1093/bjs/znaa041
213. Tsilimigras DI, Bagante F, Moris D, Hyer JM, Sahara K, Paredes AZ, et al. Recurrence patterns and outcomes after resection of hepatocellular carcinoma within and beyond the Barcelona clinic liver cancer criteria. Ann Surg Oncol. 2020;27(7):2321-31. https://doi.org/10.1245/s10434-020-08452-3
214. Tustumi F, Calthorpe L, Coimbra FJF, Alseidi A. Reviews, expert opinions, consensus statements, position papers, protocols, and evidence-based guidelines: what are their roles in clinical practice? Arq Bras Cir Dig. 2026;38:e1926. https://doi.org/10.1590/0102-67202025000057e1926
215. Tustumi F, Coelho FF, Magalhães DP, Silveira Júnior S, Jeismann VB, Fonseca GM, et al. Treatment of hepatocellular carcinoma with macroscopic vascular invasion: A systematic review and network meta-analysis. Transplant Rev. 2023;37(3):100763. https://doi.org/10.1016/j.trre.2023.100763
216. Tustumi F, Ernani L, Coelho FF, Bernardo WM, Junior SS, Kruger JAP, et al. Preoperative strategies to improve resectability for hepatocellular carcinoma: a systematic review and meta-analysis. HPB. 2018;20(12):1109-18. https://doi.org/10.1016/j.hpb.2018.06.1798
217. Venkat R, Hannallah JR, Krouse RS, Maegawa FB. Preoperative thrombocytopenia and outcomes of hepatectomy for hepatocellular carcinoma. J Surg Res. 2016;201(2):498-505. https://doi.org/10.1016/j.jss.2015.08.038
218. Viana MFF, Braga AA, Carvalho LB, Vasconcellos DCMS, Alexandrino BCMR, Coimbra FJF. Liver resection versus radiofrequency ablation or transarterial chemoembolization for early multinodular BCLC-A hepatocellular carcinoma: a systematic review and meta-analysis. J Liver Cancer. 2026;26(1):157-68. https://doi.org/10.17998/jlc.2026.02.21
219. Vibert E, Azoulay D, Hoti E, Iacopinelli S, Samuel D, Salloum C, et al. Progression of alphafetoprotein before liver transplantation for hepatocellular carcinoma in cirrhotic patients: a critical factor. Am J Transplant. 2010;10(1):129-37. https://doi.org/10.1111/j.1600-6143.2009.02750.x
220. Violi NV, Duran R, Guiu B, Cercueil JP, Aubé C, Digklia A, et al. Efficacy of microwave ablation versus radiofrequency ablation for the treatment of hepatocellular carcinoma in patients with chronic liver disease: a randomised controlled phase 2 trial. Lancet Gastroenterol Hepatol. 2018;3(5):317-25. https://doi.org/10.1016/S2468-1253(18)30029-3
221. Vilgrain V, Pereira H, Assenat E, Guiu B, Ilonca AD, Pageaux GP, et al. Efficacy and safety of selective internal radiotherapy with yttrium-90 resin microspheres compared with sorafenib in locally advanced and inoperable hepatocellular carcinoma (SARAH): an open-label randomised controlled phase 3 trial. Lancet Oncol. 2017;18(12):1624-36. https://doi.org/10.1016/S1470-2045(17)30683-6
222. Vitale A, Trevisani F, Farinati F, Cillo U. Treatment of hepatocellular carcinoma in the precision medicine era: from treatment stage migration to therapeutic hierarchy. Hepatology. 2020;72(6):2206-18. https://doi.org/10.1002/hep.31187
223. Vivarelli M, Cucchetti A, La Barba G, Ravaioli M, Gaudio M, Lauro A, et al. Liver transplantation for hepatocellular carcinoma under calcineurin inhibitors: reassessment of risk factors for tumor recurrence. Ann Surg. 2008;248(5):857-62. https://doi.org/10.1097/SLA.0b013e3181896278
224. Vivarelli M, Cucchetti A, Piscaglia F, La Barba G, Bolondi L, Cavallari A, et al. Analysis of risk factors for tumor recurrence after liver transplantation for hepatocellular carcinoma: key role of immunosuppression. Liver Transpl. 2005;11(5):497-503. https://doi.org/10.1002/lt.20391
225. Wang K, Xiang YJ, Yu HM, Cheng YQ, Liu ZH, Qin YY, et al. Adjuvant sintilimab in resected high-risk hepatocel-

lular carcinoma: a randomized, controlled, phase 2 trial. Nat Med. 2024;30(3):708-15. https://doi.org/10.1038/s41591-023-02786-7

226. Wang L, Luo B, Zhao M, Shen J. Transarterial chemoembolization combined with immunotherapy and targeted therapy as first-line treatment for unresectable and non-metastatic hepatocellular carcinoma: a meta-analysis of phase III trials. Ther Adv Gastroenterol. 2025;18:17562848251396424. https://doi.org/10.1177/17562848251396424
227. Wang Y, Lu S, Tan X, Xie S, Liang G, Liang H, et al. Liver resection in stage 0-A HCC in segments 7/8: a propensity-matched analysis comparing open, laparoscopic, and robotic approach. Surg Endosc. 2025;39(3):1902-14. https://doi.org/10.1007/s00464-024-11521-3
228. Wang YY, Zhao XH, Ma L, Ye JZ, Wu FX, Tang J, et al. Comparison of the ability of Child-Pugh score, MELD score, and ICG-R15 to assess preoperative hepatic functional reserve in patients with hepatocellular carcinoma. J Surg Oncol. 2018;118(3):440-5. https://doi.org/10.1002/jso.25184
229. Watanabe Y, Aikawa M, Kato T, Takase K, Watanabe Y, Okada K, et al. Influence of Child-Pugh B7 and B8/9 cirrhosis on laparoscopic liver resection for hepatocellular carcinoma: a retrospective cohort study. Surg Endosc. 2023;37(2):1316-33. https://doi.org/10.1007/s00464-022-09677-x
230. Wright AS, Lee FT Jr., Mahvi DM. Hepatic microwave ablation with multiple antennae results in synergistically larger zones of coagulation necrosis. Ann Surg Oncol. 2003;10(3):275-83. https://doi.org/10.1245/aso.2003.03.045
231. Xi M, Yang Z, Hu L, Fu Y, Hu D, Zhou Z, et al. Radiofrequency ablation versus stereotactic body radiotherapy for recurrent small hepatocellular carcinoma: a randomized, open-label, controlled trial. J Clin Oncol. 2025;43(9):1073-82. https://doi.org/10.1200/JCO-24-01532
232. Yang A, Ju W, Yuan X, Han M, Wang X, Guo Z, et al. Comparison between liver resection and liver transplantation on outcomes in patients with solitary hepatocellular carcinoma meeting UNOS criteria: a population-based study of the SEER database. Oncotarget. 2017;8(57):97428-38. https://doi.org/10.18632/oncotarget.22134
233. Yang Z, Wang S, Tian XY, Xie QF, Zhuang L, Li QY, et al. Impact of treatment modalities on patients with recurrent hepatocellular carcinoma after liver transplantation: Preliminary experience. Hepatobiliary Pancreat Dis Int. 2020;19(4):365-70. https://doi.org/10.1016/j.hbpd.2020.06.002
234. Yao FY, Bass NM, Nikolai B, Merriman R, Davern TJ, Kerlan R, et al. A follow-up analysis of the pattern and predictors of dropout from the waiting list for liver transplantation in patients with hepatocellular carcinoma: implications for the current organ allocation policy. Liver Transpl. 2003;9(7):684-92. https://doi.org/10.1053/jlts.2003.50147
235. Yao FY, Xiao L, Bass NM, Kerlan R, Ascher NL, Roberts JP. Liver transplantation for hepatocellular carcinoma: validation of the UCSF-expanded criteria based on preoperative imaging. Am J Transplant. 2007;7(11):2587-96. https://doi.org/10.1111/j.1600-6143.2007.01965.x
236. Ye Y, Wang Y, Xu H, Yi F. Network meta-analysis of adjuvant treatments for patients with hepatocellular carcinoma after curative resection. BMC Gastroenterol. 2023;23(1):320. https://doi.org/10.1186/s12876-023-02955-5
237. Yin L, Li H, Li AJ, Lau WY, Pan ZY, Lai EC, et al. Partial hepatectomy vs. transcatheter arterial chemoembolization for resectable multiple hepatocellular carcinoma beyond Milan Criteria: a RCT. J Hepatol. 2014;61(1):82-8. https://doi.org/10.1016/j.jhep.2014.03.012
238. Yoon JH, Choi SK. Management of early-stage hepatocellular carcinoma: challenges and strategies for optimal outcomes. J Liver Cancer. 2023;23(2):300-15. https://doi.org/10.17998/jlc.2023.08.27
239. Yopp A, Chen M, Cheng AL, Kaseb A, Kudo M, Lee HC, et al. Updated data from IMbrave050: Adjuvant atezolizumab plus bevacizumab for high-risk hepatocellular carcinoma. J Hepatol. 2026;84(6):1102-11. https://doi.org/10.1016/j.jhep.2026.01.006
240. Yu J, Yu XL, Han ZY, Cheng ZG, Liu FY, Zhai HY, et al. Percutaneous cooled-probe microwave versus radiofrequency ablation in early-stage hepatocellular carcinoma: a phase III randomised controlled trial. Gut. 2017;66(6):1172-3. https://doi.org/10.1136/gutjnl-2016-312629
241. Zeng Y, Wang Z, Lin S, Yan Y. Application of hepatic artery interventional therapies in the conversion treatment of unresectable hepatocellular carcinoma: A systematic review and meta-analysis. Am J Surg. 2026;252:116712. https://doi.org/10.1016/j.amjsurg.2025.116712
242. Zhang L, Liu P, Zhuang L, Ling S, Zhan Q, Zhou W, et al. mTOR inhibitor reduces nontumour-related death in liver transplantation for hepatocellular carcinoma. Mol Biomed. 2024;5(1):9. https://doi.org/10.1186/s43556-024-00170-6
243. Zhang Z, Zhang Y, Wang W, Hua Y, Liu L, Shen S, et al. Thrombocytopenia and the outcomes of hepatectomy for hepatocellular carcinoma: a meta-analysis. J Surg Res. 2017;210:99-107. https://doi.org/10.1016/j.jss.2016.11.002
244. Zhang ZY, Dong KS, Zhang EL, Zhang LW, Chen XP, Dong HH. Resection might be a meaningful choice for hepatocellular carcinoma with portal vein thrombosis: A systematic review and meta-analysis. Medicine. 2019;98(50):e18362. https://doi.org/10.1097/MD.0000000000018362
245. Zhong BY, Jin ZC, Chen JJ, Zhu HD, Zhu XL. Role of transarterial chemoembolization in the treatment of hepatocellular carcinoma. J Clin Transl Hepatol. 2023;11(2):480-9. https://doi.org/10.14218/JCTH.2022.00293
246. Zhu B, Wang J, Li H, Chen X, Zeng Y. Living or deceased organ donors in liver transplantation for hepatocellular carcinoma: a systematic review and meta-analysis. HPB. 2019;21(2):133-47. https://doi.org/10.1016/j.hpb.2018.11.004